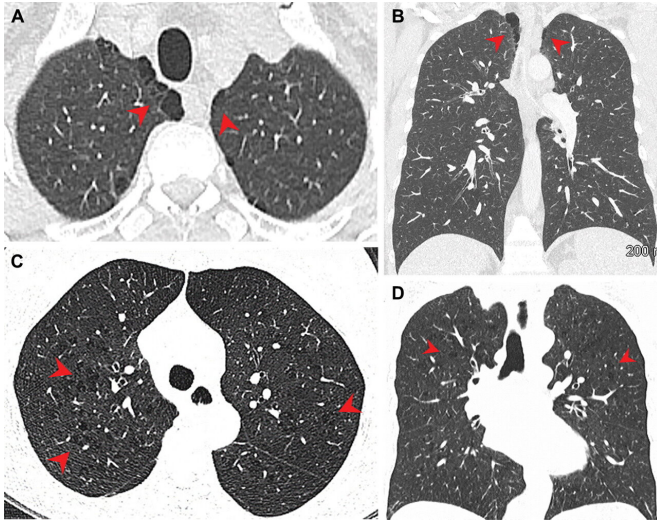


# Imaging study: Marijuana smokers show higher rates of emphysema, airway diseases than tobacco smokers

15 November 2022



Pulmonary emphysema in (A, B) marijuana and (C, D) tobacco smokers. (A) Axial and (B) coronal CT images in a 44-year-old male marijuana smoker show paraseptal emphysema (arrowheads) in bilateral upper lobes. (C) Axial and (D) coronal CT images in a 66-year-old female tobacco smoker with centrilobular emphysema represented by areas of centrilobular lucency (arrowheads). Credit: *Radiology* (2022). DOI: 10.1148/radiol.212611

Researchers from the University of Ottawa and The Ottawa Hospital have found marijuana smokers have a higher rate of emphysema and airway diseases compared to cigarette smokers.

The findings, published in *Radiology*, examined the chest CT examinations of 56 marijuana smokers, 57 non-smokers and 33 tobacco-only smokers between 2005 and 2020. They determined higher rates of paraseptal emphysema and airway inflammatory changes, such as bronchiectasis, bronchial wall thickening, and mucoid impaction, in the marijuana smokers.

Giselle Revah, a [radiologist](#) and Assistant Professor in the Faculty of Medicine, was searching for answers on the effect of marijuana on the lungs and its health implications, especially with little information available in the current literature since marijuana only became legal in Canada in 2018.

"I can tell if someone is a heavy or a long-time cigarette smoker when I look at a CT scan. With marijuana being the second most inhaled substance after tobacco, I started wondering: What does marijuana inhalation look like on a CT scan? Would I be able to tell if someone was a marijuana smoker, is it different from cigarette smoke?" says Revah, a radiologist The Ottawa Hospital, where the research was conducted.

"What's unique about this study is that it there hasn't been anything comparing the imaging findings in tobacco smokers to marijuana smokers before. In fact, there is a lack of imaging research in marijuana, probably because it's still illegal in many parts of the world, and in many U.S. states, which is why I think we were the first to do a project like this."

Despite the [small sample size](#), Revah's findings suggest that marijuana smokers saw additional effects on the lungs above tobacco alone, including more instances of large and small airways diseases.

"We've identified an association between [marijuana](#) smoking and damage to both the small and the large airways," she said. "We still need more research before we can affect [policy change](#). We need larger, more robust prospective studies with more patients to confirm it."

**More information:** Luke Murtha et al, Chest CT Findings in Marijuana Smokers, *Radiology* (2022).

[DOI: 10.1148/radiol.212611](https://doi.org/10.1148/radiol.212611)

Provided by University of Ottawa

APA citation: Imaging study: Marijuana smokers show higher rates of emphysema, airway diseases than tobacco smokers (2022, November 15) retrieved 2 December 2022 from

<https://medicalxpress.com/news/2022-11-imaging-marijuana-smokers-higher-emphysema.html>

*This document is subject to copyright. Apart from any fair dealing for the purpose of private study or research, no part may be reproduced without the written permission. The content is provided for information purposes only.*