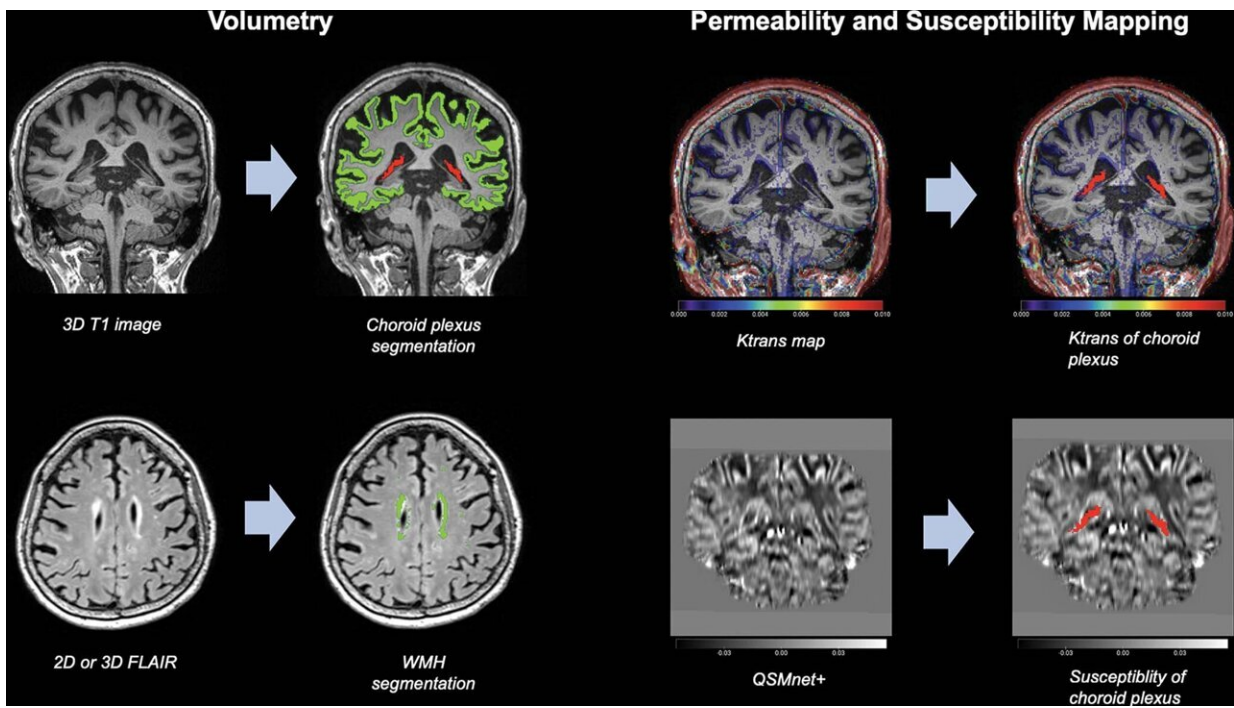


Choroid plexus volume linked to Alzheimer's disease

May 17 2022



MRI processing steps. For volumetry (left), choroid plexus (CP) volume (red) and cerebral cortex volume (green) are segmented from T1-weighted volumetric images by using an automatic volumetric software (Inbrain) based on the FreeSurfer 6.0 platform (upper row). White matter hyperintensity (WMH) volumes (green) are also segmented from three-dimensional (3D) or two-dimensional (2D) fluid-attenuated inversion-recovery (FLAIR) images by using the same software (lower row). The segmented mask volumes are binary. For permeability and susceptibility mapping (right), permeability values (volume transfer constant [Ktrans] and fractional plasma volume) are obtained from dynamic contrast-enhanced MRI scans by using the Patlak model, and CP permeability values are extracted with use of coregistration of the segmented CP

(red) of T1-weighted images to the parametric map using a mutual information-based algorithm (upper row). The color scale bar represents the volume transfer constant (in min^{-1}). CP susceptibility measures are generated in an analogous manner. Quantitative susceptibility mapping (QSM) is obtained from multidynamic multiecho images by using QSMnet1 (lower row). The grayscale bar represents susceptibility in parts per million. Credit: Radiological Society of North America

Increased volume of an important structure in the brain called the choroid plexus is linked to greater cognitive impairment and Alzheimer's disease, according to a new study published in the journal *Radiology*.

The choroid plexus is a network of blood vessels, [connective tissue](#) and cells found in spaces of the brain called ventricles. The plexus plays an important role in brain health. It is a gateway for [immune cells](#) from the blood to the brain. As the primary site for the production of cerebrospinal fluid, it is crucial to clearing waste products and toxic proteins from [brain cells](#). This role is particularly important in the case of Alzheimer's disease. Recent research suggests that [disease progression](#) is related to the accumulation of abnormal proteins called amyloid and tau and subsequent degeneration of the nerves.

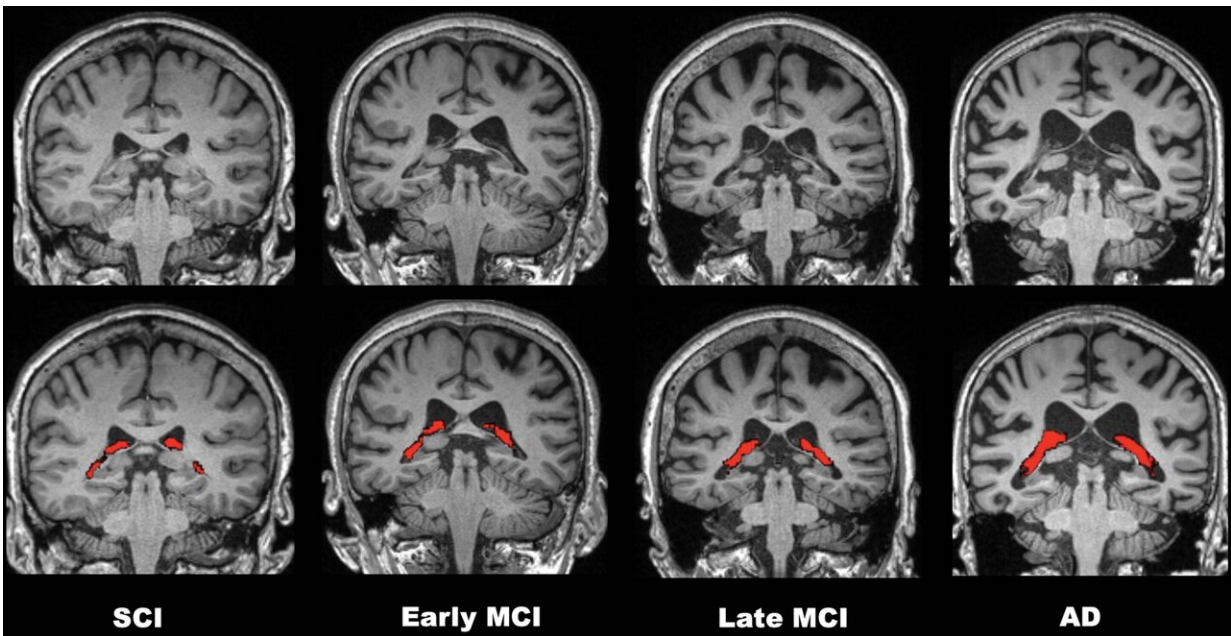
"Researchers believe impaired clearance rather than overproduction of abnormal amyloid and tau is responsible for Alzheimer's disease," said study senior author Won-Jin Moon, M.D., Ph.D., professor of radiology and chairperson of the Department of Radiology at the Konkuk University School of Medicine in Seoul, Korea. "Thus, we assume that the abnormal status of choroid plexus is linked to the failure of clearance leading to waste and toxic protein accumulation in the brain and failure of immune surveillance leading to neuroinflammation."

Little is known about the choroid plexus' imaging profile in cognitive

impairment.

To learn more, Dr. Moon and colleagues performed brain MRI on 532 participants at various stages of cognitive impairment. Of the 532 participants, 132 underwent permeability imaging using dynamic contrast-enhanced MRI.

Choroid plexus volume and permeability were associated with the severity of cognitive impairment on brain MRI. Choroid plexus volume was greater in those with Alzheimer's dementia than in those without. Higher choroid plexus volume was negatively associated with memory. It also had negative effects on executive function, a wide-ranging set of mental skills governing things like self-control and planning.



Comparisons of four representative 3.0-T brain MRI scans of choroid plexus (CP) volume (red) according to disease stage over the cognitive impairment spectrum. CP volume is greater in the patient with Alzheimer disease (AD) than in those with subjective cognitive impairment (SCI) or mild cognitive impairment (MCI). All patients were 75-year-old women. Credit: Radiological

Society of North America

"Our study found that the enlarged choroid plexus volume is independently associated with increased cognitive impairment," Dr. Moon said. "We found no relationship between choroid plexus volume and amyloid pathology but a clear relationship between the choroid plexus volume and [cognitive impairment](#) severity."

The study results point to new possibilities for MRI's role in the diagnosis of Alzheimer's disease.

"I think our findings on the choroid plexus can suggest it as a new potential MR imaging surrogate for an impaired clearance system and neuroinflammation," Dr. Moon said.

Other potential clinical applications include helping researchers develop new target drugs or treatments for clearance failure and neuroinflammation. Eventually, choroid plexus measurements could help speed treatment to those who need it most.

"If we combine choroid plexus volume and hippocampal volume in a screening stage, it may help us better discriminate the more vulnerable patients from the less vulnerable ones," Dr. Moon said.

The researchers plan to follow up with a [longitudinal study](#). They will explore changes in [choroid plexus](#) volume over time as the disease progresses.

More information: Jong Duck Choi et al, Choroid Plexus Volume and Permeability at Brain MRI within the Alzheimer Disease Clinical Spectrum, *Radiology* (2022). [DOI: 10.1148/radiol.212400](https://doi.org/10.1148/radiol.212400)

Provided by Radiological Society of North America

Citation: Choroid plexus volume linked to Alzheimer's disease (2022, May 17) retrieved 12 July 2023 from <https://medicalxpress.com/news/2022-05-choroid-plexus-volume-linked-alzheimer.html>

This document is subject to copyright. Apart from any fair dealing for the purpose of private study or research, no part may be reproduced without the written permission. The content is provided for information purposes only.