

# An improved elbow MRI view for Major League Baseball pitchers

June 4 2021

---



Credit: CC0 Public Domain

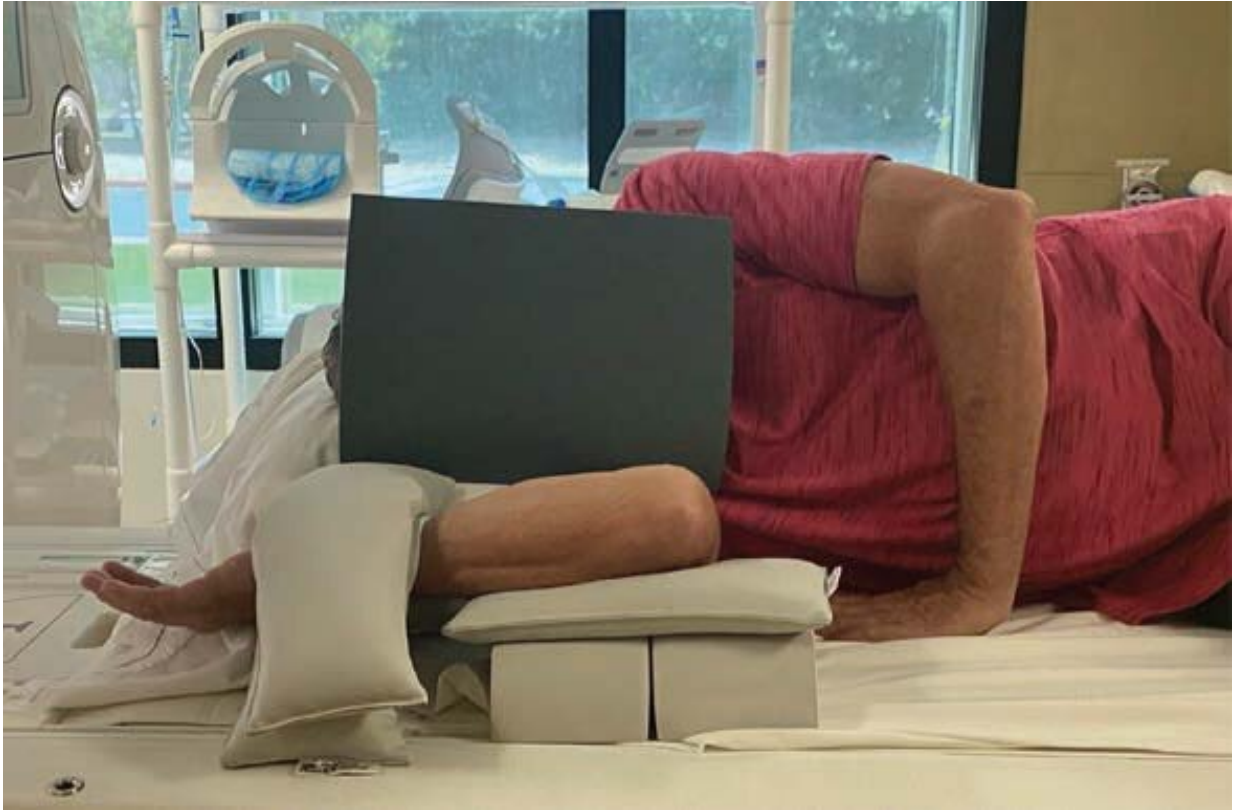According to a pilot study published in ARRS' *American Journal of Roentgenology* (AJR), the flexed elbow valgus external rotation (FEVER) view can improve MRI evaluation of the ulnar collateral ligament (UCL)

in Major League Baseball (MLB) pitchers.

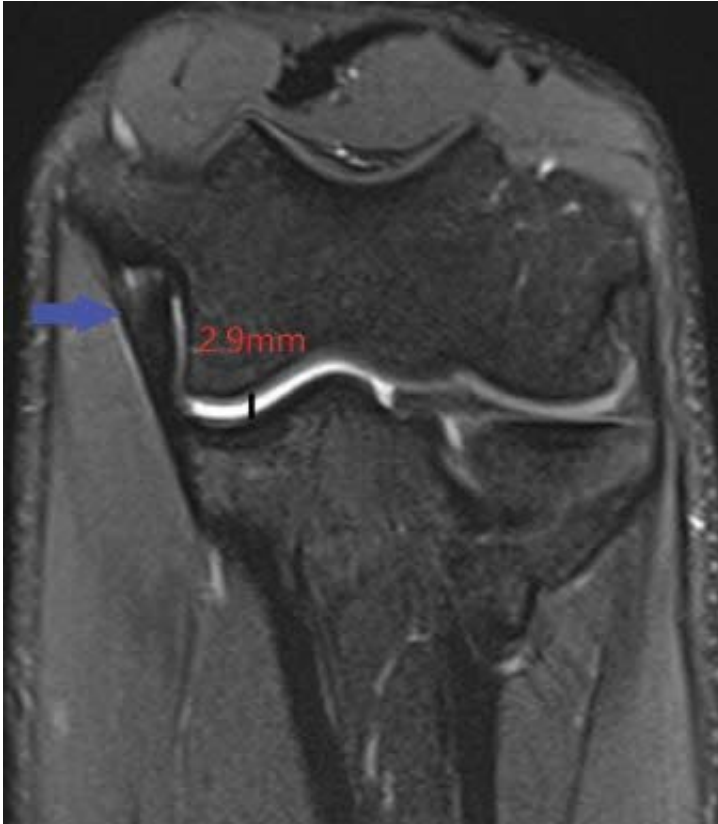"The increased joint space width confirms elbow valgus stress with FEVER view," wrote corresponding author Thomas Knoblauch at the University of Nevada Las Vegas. "Diagnostic confidence increased, and additional UCLs were identified as abnormal."

Due to repetitive extreme valgus stress during overhead throwing maneuvers, UCL injuries remain common in throwing athletes. Because standard positioning for elbow MRI is often suboptimal for UCL rendering, Knoblauch, Arizona Diamondbacks head team physician Gary Waslewski, and colleagues piloted their study to assess FEVER view impact on ulnotrochlear (UT) joint space measurement and UCL reader evaluation, as incorporated with conventional elbow MRI.

A total of 44 MLB pitchers underwent elbow MRI, including both standard sequences and a coronal fat-saturated proton density-weighted sequence in the FEVER view using specific positioning maneuvers and sandbags to immobilize the elbow in valgus stress, while visualizing the UCL parallel to its long axis. To measure UT joint space and assess confidence in UCL-related findings with overall UCL normality, two radiologists independently evaluated standard and FEVER views.

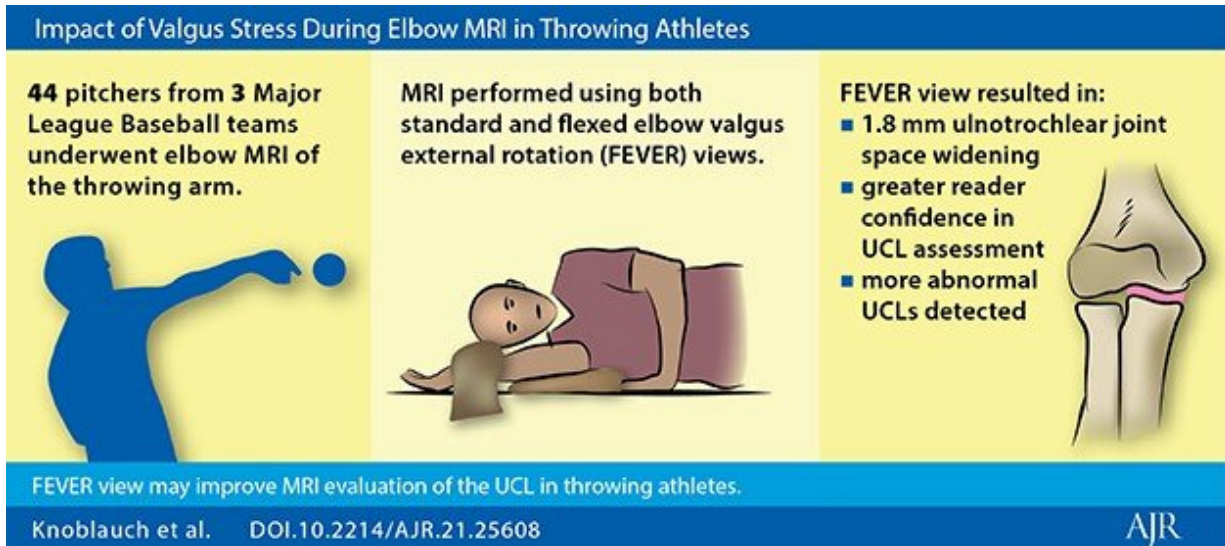


Note elevated flexed elbow and sandbags to induce valgus stress. Elbow coil is not included in image. Credit: American Roentgen Ray Society (ARRS), *American Journal of Roentgenology* (AJR)



20-year-old male pitcher shows normal anterior bundle of UCL (blue arrow) and 2.9 mm UT articular width. Credit: American Roentgen Ray Society (ARRS), *American Journal of Roentgenology* (AJR)

"Among 44 MLB pitchers undergoing elbow MRI," Knoblauch et al. continued, "the FEVER view, compared with standard view, yielded increased UT joint space width (mean increase, 1.80mm) and increased confidence for three of five UCL-related findings (mean increase, -0.14 to 0.98)." Readers 1 and 2 classified 3 and 2 additional UCLs as abnormal on FEVER compared with standard view; neither reader classified any UCL as abnormal in standard view but normal in FEVER view.



"The findings support the FEVER view as a practical addition to standard elbow MRI protocols for achieving elbow valgus stress in throwing athletes," the authors of this AJR article concluded, "thereby providing functional information to complement the high-resolution anatomic assessment provided by MRI." Credit: American Roentgen Ray Society (ARRS), *American Journal of Roentgenology* (AJR)

"The findings support the FEVER view as a practical addition to standard elbow MRI protocols for achieving [elbow](#) valgus stress in throwing athletes," the authors of this AJR article concluded, "thereby providing functional information to complement the high-resolution anatomic assessment provided by MRI."

**More information:** Pamela J. Lund et al, FEVER: The Flexed Elbow Valgus External Rotation View for MRI Evaluation of the Ulnar Collateral Ligament in Throwing Athletes—A Pilot Study in Major League Baseball Pitchers, *American Journal of Roentgenology* (2021). [DOI: 10.2214/AJR.21.25608](https://doi.org/10.2214/AJR.21.25608)

Provided by American Roentgen Ray Society

Citation: An improved elbow MRI view for Major League Baseball pitchers (2021, June 4)  
retrieved 23 November 2023 from

<https://medicalxpress.com/news/2021-06-elbow-mri-view-major-league.html>

<p>This document is subject to copyright. Apart from any fair dealing for the purpose of private study or research, no part may be reproduced without the written permission. The content is provided for information purposes only.</p>
--