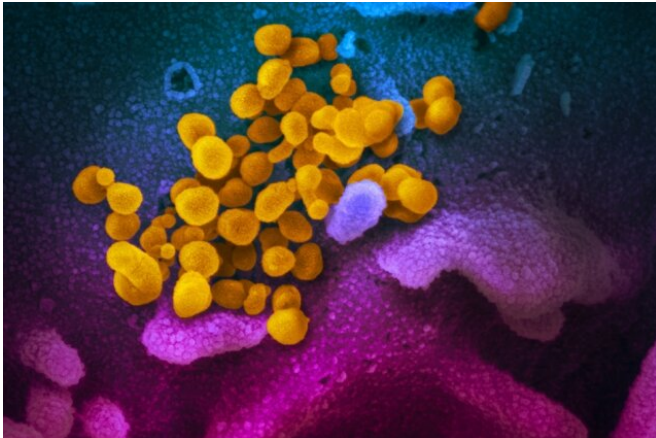


# Presence and prevalence of salivary gland ectasia and oral disease in COVID-19 survivors

3 March 2021



This scanning electron microscope image shows SARS-CoV-2 (yellow)—also known as 2019-nCoV, the virus that causes COVID-19—isolated from a patient, emerging from the surface of cells (blue/pink) cultured in the lab. Credit: NIAID-RML

The clinical picture of COVID-19 in various target organs has been extensively studied and described, but relatively little is known about the characteristics of oral cavity involvement. The study "Frequent and Persistent Salivary Gland Ectasia and Oral Disease After COVID-19" published in the *Journal of Dental Research (JDR)*, investigated the presence and prevalence of oral manifestations in COVID-19 survivors.

Researchers at the Università Vita Salute San Raffaele, Milan, Italy, profiled the oral involvement in 122 COVID-19 survivors, hospitalized and followed up at a single referral visit after a median 104 days from hospital discharge. The researchers found that oral manifestations, specifically salivary gland ectasia, were unexpectedly common being detectable in 83.9% and 43% of COVID-19 survivors, respectively. Salivary glands were

defined as being ectatic when they appeared swollen, with a patent duct, and no pus leaking. Salivary gland ectasia reflected the hyperinflammatory response to SARS-CoV-2, as demonstrated by the [significant relationship](#) with C-reactive protein and lactate dehydrogenase (LDH) levels at hospital admission, and with the use of antibiotics during acute disease. Both LDH levels and antibiotic administration survived as independent predictors of salivary [gland](#) ectasia in a multivariable analysis. Temporomandibular joint abnormalities, facial pain and masticatory muscle weakness were also common.

"This retrospective and prospective cohort study of COVID-19 survivors revealed that residual damage of the oral cavity persists in the vast majority of the more severely affected patients far beyond clinical recovery," said JDR Editor-in-Chief Nicholas Jakobovics, Newcastle University, England. "This suggests that the [oral cavity](#) represents a preferential target for SARS-CoV-2 infection. Further studies are needed to clarify the connection between SARS-CoV-2 infection and oral disorders."

**More information:** E.F. Gherlone et al, Frequent and Persistent Salivary Gland Ectasia and Oral Disease After COVID-19, *Journal of Dental Research* (2021). [DOI: 10.1177/0022034521997112](#)

Provided by International & American Associations for Dental Research

APA citation: Presence and prevalence of salivary gland ectasia and oral disease in COVID-19 survivors (2021, March 3) retrieved 28 May 2022 from <https://medicalxpress.com/news/2021-03-presence-prevalence-salivary-gland-ectasia.html>

*This document is subject to copyright. Apart from any fair dealing for the purpose of private study or research, no part may be reproduced without the written permission. The content is provided for information purposes only.*