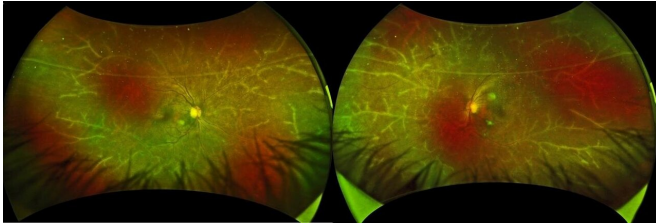


# The natural artistry of disease: A wintry landscape in the eye

9 November 2020



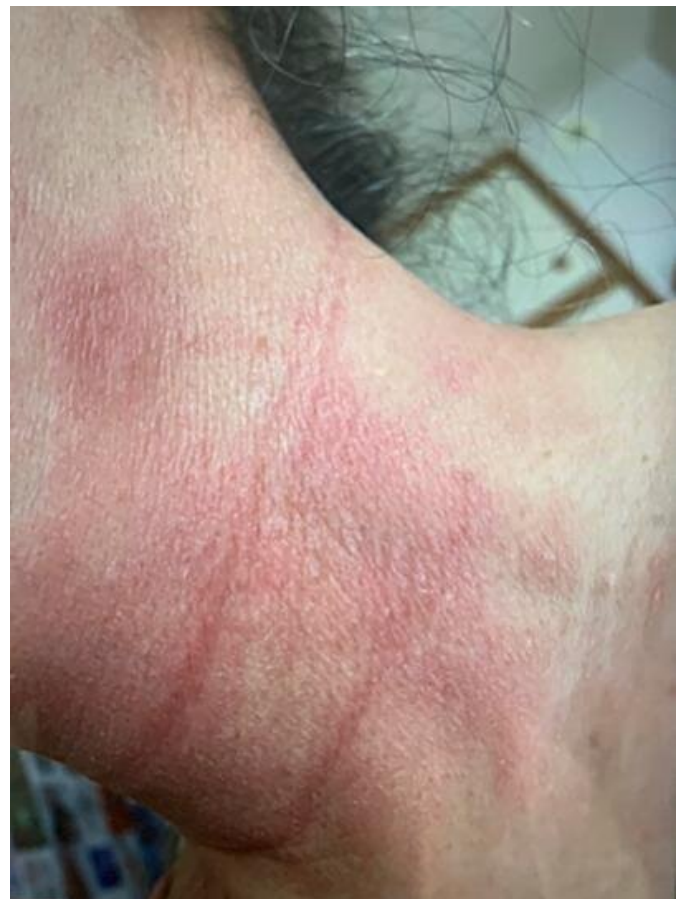Koju Kamoi, lead/corresponding author, describes the remarkably picturesque funduscopy findings. "Along the retinal blood vessels, a translucent sheath was visible resembling the icy branches of a tree in winter. We recognized this as frosted branch angiitis, a rare presentation of florid retinal vasculitis."

Widefield imaging of frosted branch angiitis. Credit: Department of Ophthalmology and Visual Science, TMDU

Leukemias and lymphomas are life-threatening malignancies affecting white blood cells and the immune system; fortunately, radiotherapy and chemotherapy, combined with stem cell therapy, can improve survival significantly. Now, Japanese researchers report one such patient who presented with an intriguing and rare delayed ocular complication descriptively named frosted branch angiitis.

A Japanese woman in her early fifties was diagnosed with acute-type adult T-cell leukemia-lymphoma associated with human T-cell lymphotropic virus type 1 (HTLV-1). She was managed with whole body irradiation and [anti-cancer drugs](#), followed by allogeneic (donor) human stem cell transplant (HSCT). HSCT allows physicians to use higher doses of chemoradiotherapy as the patient gets an infusion (transplant) of blood-forming stem [cells](#) to restore collaterally damaged bone marrow. The patient went into remission and had no complications for several years.

Over four years after HSCT, she developed blurred vision and was referred for further examination. A slit-lamp biomicroscope, which shines a thin sheet of light into the eye for inspection, revealed cellular infiltrates in both segments. Associate Professor



A skin rash around her neck. Credit: Department of Ophthalmology and Visual Science, TMDU

The medical team ran a battery of tests to rule out recurrence, other autoimmune disease, and bacterial, viral or fungal infections. Therefore, the

physicians concluded that the frosted branch angiitis resulted from immune activation following HSCT. First described in the Japanese literature by Ito in 1976 occurring in a six-year-old child, frosted branch angiitis is very rare, with most cases reported from Japan and sporadically from other countries.

The patient was treated with corticosteroids to suppress inflammation. After six months the lesion regressed but steroids were continued for over a year. Surprisingly, a month after stopping systemic steroids, the patient developed a skin rash and dryness of both eyes. "This sequence of events suggests that frosted branch angiitis was likely the first sign of systemic inflammation," explains Dr. Kamoi. "Steroids could have suppressed the slower skin and eye-surface changes that were expressed following discontinuation."

"Though HSCT is beneficial in many situations, it may activate the [immune system](#) adversely," warns Professor Kyoko Ohno-Matsui, senior author. "Frosted [branch](#) angiitis could serve as early warning sign of inflammation elsewhere in the body. Therefore, intraocular monitoring is warranted in these patients."

**More information:** Koju Kamoi et al, Frosted branch angiitis after allogeneic haematopoietic stem cell transplantation in adult T-cell leukaemia-lymphoma, *The Lancet Haematology* (2020). [DOI: 10.1016/S2352-3026\(20\)30226-X](https://doi.org/10.1016/S2352-3026(20)30226-X)

Provided by Tokyo Medical and Dental University

APA citation: The natural artistry of disease: A wintry landscape in the eye (2020, November 9) retrieved 11 October 2022 from

<https://medicalxpress.com/news/2020-11-natural-artistry-disease-wintery-landscape.html>

*This document is subject to copyright. Apart from any fair dealing for the purpose of private study or research, no part may be reproduced without the written permission. The content is provided for information purposes only.*