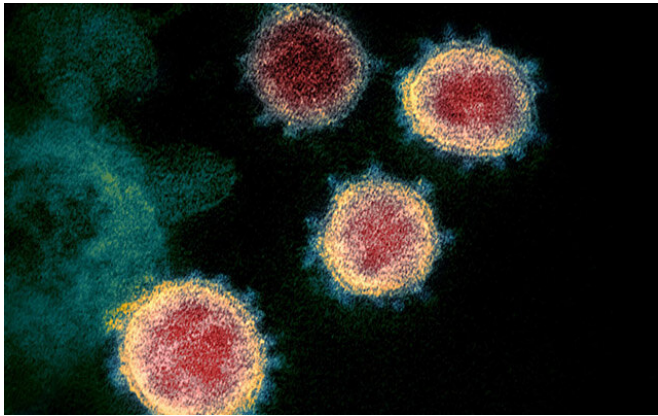


# First COVID-19 autopsy series reveals new cardiopulmonary findings

27 May 2020



A colorized scanning electron micrograph of the SARS-CoV-2 virus. Credit: NIAID

LSU Health New Orleans pathologists performed the first series of autopsies on African Americans who died from COVID-19 in New Orleans, and their findings provide new and critical information to guide patient management. The findings are published in *The Lancet Respiratory Medicine*.

"We found that the small vessels and capillaries in the lungs were obstructed by blood clots and associated hemorrhage that significantly contributed to decompensation and death in these patients," reports senior author Richard Vander Heide, MD, Ph.D., Professor and Director of Pathology Research at LSU Health New Orleans School of Medicine. "We also found elevated levels of D-dimers—fragments of proteins involved in breaking down blood clots. What we did not see was myocarditis, or inflammation of the heart muscle, that early reports suggested significantly contributes to death from COVID-19."

The patients were both males and females between 40 and 70 years old. All were African American and many had a history of hypertension,

obesity, and insulin-dependent type II diabetes, and [chronic kidney disease](#). In all cases, the patients presented to the hospital approximately three days to one week after developing a mild cough and fever (to 101-102° F), experiencing sudden respiratory decompensation or collapse at home. Chest X-rays revealed "bilateral ground-glass opacities," findings consistent with [acute respiratory distress syndrome](#) (ARDS).

While the LSU Health New Orleans pathologists also found the same widespread damage in the lung structures involved in gas exchange seen in the first SARS epidemic, the small vessel clotting is a new finding that appears to be specific to COVID caused by SARS-CoV-2.

"Our study presents a large series of autopsies within a specific demographic experiencing the highest rate of adverse outcomes within the United States," notes Sharon Fox, MD, Ph.D., Associate Director of Research and Development in the Department of Pathology at LSU Health New Orleans School of Medicine.

The autopsies were performed at University Medical Center in New Orleans, which was built after Hurricane Katrina. It is one of the few hospitals in the United States equipped with an autopsy suite that meets CDC standards for performing autopsy of COVID-19 positive patients safely.

"The key implications of our study include the discovery of a mechanism for severe pathology within the African American population, likely extendable to all persons with severe disease, and possibly a target for immediate therapeutic management," concludes Dr. Vander Heide. "The results may also be applicable to a broader demographic experiencing severe COVID-19 disease. Management of these patients should include therapy to target these pathologic mechanisms."

**More information:** *The Lancet Respiratory Medicine*, DOI: [10.1016/S2213-2600\(20\)30243-5](https://doi.org/10.1016/S2213-2600(20)30243-5) ,  
[www.thelancet.com/journals/lan ...](http://www.thelancet.com/journals/lan...)  
[/lan... \(20\)30243-5/fulltext](http://www.thelancet.com/journals/lan...)

Provided by Louisiana State University

APA citation: First COVID-19 autopsy series reveals new cardiopulmonary findings (2020, May 27)  
retrieved 21 August 2022 from <https://medicalxpress.com/news/2020-05-covid-autopsy-series-reveals-cardiopulmonary.html>

*This document is subject to copyright. Apart from any fair dealing for the purpose of private study or research, no part may be reproduced without the written permission. The content is provided for information purposes only.*