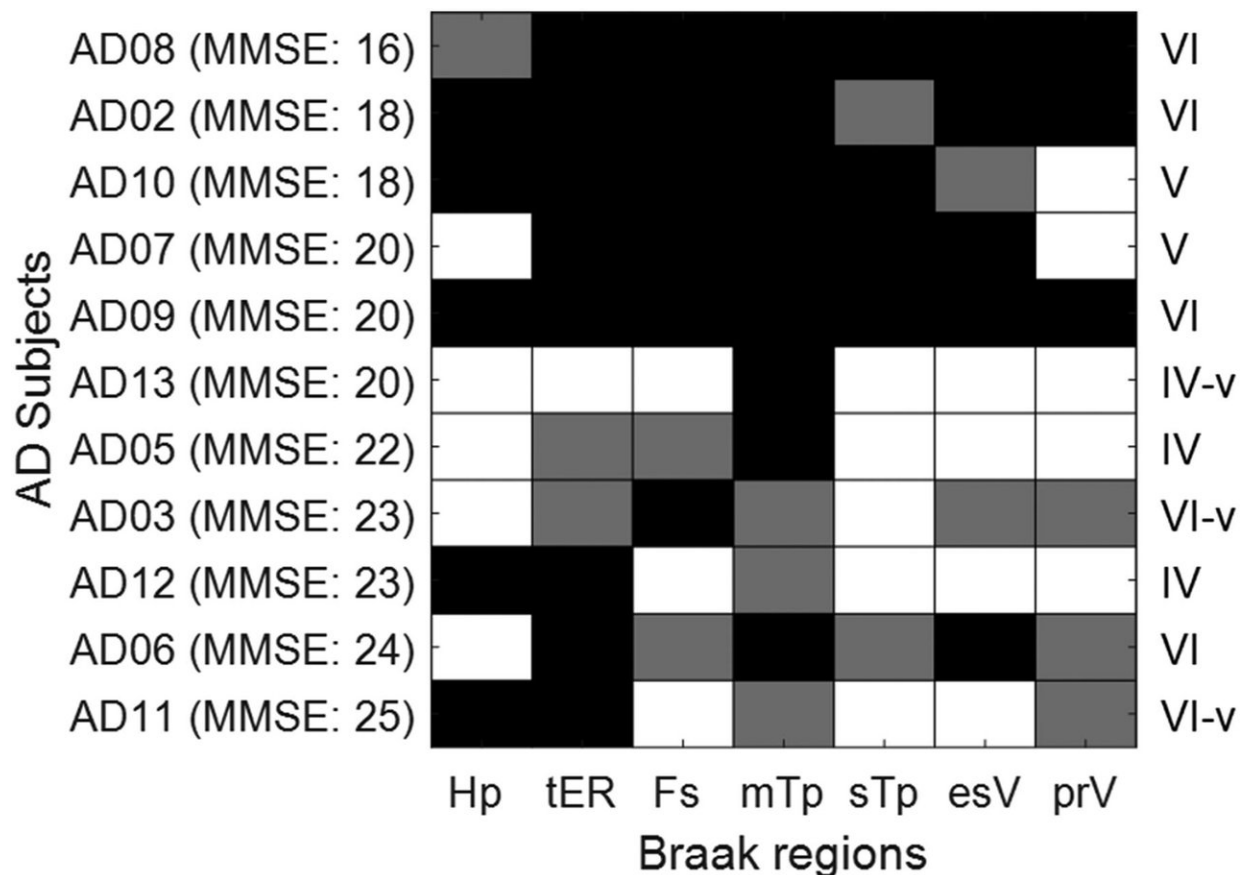


New PET tracer identified for imaging tau in Alzheimer's disease patients

December 6 2018



Checkerboard plot showing ¹⁸F-RO-948-positivity results (black cells: bilaterally positive; gray cells: unilaterally positive) of anterior and posterior Braak regions (19), and estimated Braak stages (right column) (20). esV = extrastriatal visual cortex; Fs = fusiform gyrus; Hp = hippocampus; mTp = middle temporal cortex; prV = primary visual cortex; sTp = superior temporal cortex; tER = transentorhinal cortex. Credit: DF Wong *et al.*, Johns Hopkins University, Baltimore, MD.

In the diagnosis of Alzheimer's disease and the search for effective treatments, tau tangles in the brain have joined amyloid build-up as markers of the disease and potential therapy targets. In the December issue of *The Journal of Nuclear Medicine*, the featured article of the month reports on the identification of a promising second-generation positron emission tomography (PET) tracer for imaging and measuring tau pathology.

"We compared three novel tau-specific radiopharmaceuticals—¹¹C-RO-963, ¹¹C-RO-643, and ¹⁸F-RO-948—that showed pre-clinical in vitro and in vivo promise for use in imaging human tau (Honer *et al.*, *JNM*, April 2018)," explains Dean F. Wong, MD, Ph.D., Johns Hopkins University professor of radiology, neurology, psychiatry and neurosciences and director of the Division of Nuclear Medicine's Section of High Resolution Brain PET Imaging.

In this first human evaluation of these novel radiotracers, healthy humans and patients with Alzheimer's disease (AD) were studied using an innovative study design to perform head-to-head comparisons of the three compounds in a pairwise fashion. Wong states, "This design allowed us to select one radioligand, ¹⁸F-RO-948, as the most promising second-generation tau radiopharmaceutical for larger scale use in human PET tau imaging."

Over all [brain regions](#) and subjects, the trend was for ¹⁸F-RO-948 to have the highest standardized uptake value (SUV_{peak}), followed by ¹¹C-RO-963 and then ¹¹C-RO-643. Regional analysis of SUV ratio and total distribution volume for ¹¹C-RO-643 and ¹⁸F-RO-948 clearly discriminated the AD group from the healthy control groups. Compartmental modeling confirmed that ¹¹C-RO-643 had lower brain entry than either ¹¹C-RO-963 or ¹⁸F-RO-948 and that ¹⁸F-RO-948

showed better contrast between areas of high versus low tau accumulation.

Subsequent analysis therefore focused on 18F-RO-948. Both voxelwise and region-based analysis of 18F-RO-948 binding in healthy controls versus AD subjects revealed multiple areas where AD subjects significantly differed from healthy controls. Voxelwise analysis also revealed a set of symmetric clusters where AD subjects had higher binding than healthy controls.

"Importantly, this new tracer appears to have much less off-target binding than was reported for existing tau tracers," notes Wong. "Especially, it has less binding to the [choroid plexus](#) adjacent to the hippocampus, which has confounded interpretation of mesial temporal tau measured by first generation PET Tau tracers."

He points out, "The significance of this research and the companion research reported in Kuwabara et al. in this same issue is that they describe in detail the selection and quantification of a second-generation tau PET imaging as a complement to amyloid imaging, allowing us to accurately measure tau pathology in living people and contributing to our understanding of the pathophysiology of Alzheimer's and related dementias. Better Tau PET radiopharmaceuticals also provide the promise of improved target engagement and monitoring of anti-tau treatments in future Alzheimer's clinical trials."

Collaboration has been key to this research process. Wong emphasizes, "These findings demonstrate the impact of the complementary strengths of preclinical, translational and clinical research with university PET and memory experts, NIH aging experts and dedicated imaging neuroscientists in the pharmaceutical industry to approach one of the greatest global public health challenges—i.e., Alzheimer's disease, where there is still no definitive cure. Improved biomarkers such as PET

imaging of tau and, in the future, other dementia-implicated proteins are vital to reducing the enormous costs of drug development (typically \$1B-\$2B a year per drug) and eventually understanding and treating Alzheimer's."

More information: Dean F. Wong et al, Characterization of 3 Novel Tau Radiopharmaceuticals, 11C-RO-963, 11C-RO-643, and 18F-RO-948, in Healthy Controls and in Alzheimer Subjects, *Journal of Nuclear Medicine* (2018). [DOI: 10.2967/jnumed.118.209916](https://doi.org/10.2967/jnumed.118.209916)

Provided by Society of Nuclear Medicine and Molecular Imaging

Citation: New PET tracer identified for imaging tau in Alzheimer's disease patients (2018, December 6) retrieved 18 December 2023 from <https://medicalxpress.com/news/2018-12-pet-tracer-imaging-tau-alzheimer.html>

This document is subject to copyright. Apart from any fair dealing for the purpose of private study or research, no part may be reproduced without the written permission. The content is provided for information purposes only.