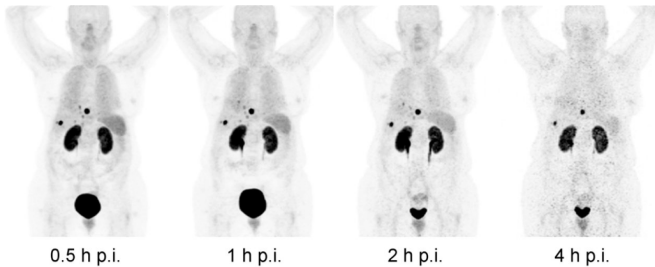


New nuclear medicine method shows promise for better detection of neuroendocrine tumors

6 June 2018



PET maximum intensity projections with a constant linear gray scale show multiple liver metastases and subdiaphragmatic peritoneal deposits. Tumor and renal uptake persist over time while organs such as spleen, lungs and liver, along with the urinary excretion, are progressively washed out. The highest tumor contrast was found at 1 h post injection, while 4h images suffer from poor count statistics. There is remarkably low accumulation of ^{68}Ga -OPS202 in sst2-positive organs such as pituitary, spleen, adrenals and uncinate process of the pancreas. Credit: GP Nicolas et al., University Hospital Basel, Basel, Switzerland

Researchers have shown that a new nuclear medicine procedure could safely and more effectively detect cancerous gastrointestinal and pancreatic neuroendocrine tumors than current methods. The study is featured in the June issue of *The Journal of Nuclear Medicine*.

Neuroendocrine tumors (NETs) can occur in almost any organ, but they are most commonly observed in the pancreas and [gastrointestinal tract](#). The average time until diagnosis is 3 to 10 years. An estimated 40 to 95 percent of cancerous gastroenteropancreatic NETs (GEP-NETs) have spread to other parts of the body (metastasized) by the time of diagnosis.

Most GEP-NETs express a high density of

somatostatin receptor subtype 2 (sst2). These receptors have, therefore, become a prime target for imaging and treating these tumors. Currently, gallium- 68 (^{68}Ga)-DOTATOC/-TATE for diagnostic imaging and lutetium- 177 (^{177}Lu)-DOTATOC/-TATE for therapy are paired for "theranostic" identification and treatment of NETs.

Preclinical and preliminary clinical evidence indicates that the novel radiolabeled tracer ^{68}Ga -OPS202, an sst antagonist with a high affinity for sst2, has the potential to perform better than an sst agonist such as ^{68}Ga -DOTATOC because ^{68}Ga -OPS202 binds to more sst receptor binding sites than sst agonists.

This first-in-human Phase 1/2 study, included 12 patients with well differentiated GEP-NETs. Based on total numbers of detected malignant lesions, the optimal time window for the scan was determined to be between 1 and 2 hours. The study shows that ^{68}Ga -OPS202 is rapidly cleared from the blood, resulting in low background activity, especially in the liver and gastrointestinal tract.

"Even though the effective dose of ^{68}Ga -OPS202 is comparable to other ^{68}Ga -labeled somatostatin analogs, there are striking differences concerning its biodistribution and organ doses such as liver, gastrointestinal tract, pancreas, lung and spleen," explains Damian Wild, MD, Ph.D., University Hospital Basel in Basel, Switzerland.

He points out, "The lower organ doses and tracer uptake of ^{68}Ga -OPS202, especially in the gastrointestinal tract and the liver, is clinically relevant, as it allows improvement of the imaging contrast ([tumor](#)-to-background ratios) and sensitivity for detecting primary tumor or liver metastases of GEP-NETs (as shown in comparison to ^{68}Ga -DOTATOC in Phase 2 of the study, also

published in the June *JNM*). Important for patients is that ^{68}Ga -OPS202 was well tolerated and did not raise any safety concerns."

Wild states, " ^{68}Ga -OPS202 could be a favorable alternative to the current radiolabeled somatostatin agonists in use in the clinic for PET/CT imaging of neuroendocrine tumor patients. In addition, due to their enhanced binding properties, radiolabeled sst antagonists may open a new avenue for PET imaging and targeted radionuclide therapy in non-neuroendocrine tumor indications. In that sense ^{68}Ga -OPS202 is the ideal theranostic companion for ^{177}Lu -OPS201 targeted radionuclide therapy."

More information: Guillaume P. Nicolas et al, Safety, Biodistribution, and Radiation Dosimetry of ^{68}Ga -OPS202 in Patients with Gastroenteropancreatic Neuroendocrine Tumors: A Prospective Phase I Imaging Study, *Journal of Nuclear Medicine* (2017). DOI: [10.2967/jnumed.117.199737](https://doi.org/10.2967/jnumed.117.199737)

Provided by Society of Nuclear Medicine and Molecular Imaging

APA citation: New nuclear medicine method shows promise for better detection of neuroendocrine tumors (2018, June 6) retrieved 8 October 2022 from <https://medicalxpress.com/news/2018-06-nuclear-medicine-method-neuroendocrine-tumors.html>

This document is subject to copyright. Apart from any fair dealing for the purpose of private study or research, no part may be reproduced without the written permission. The content is provided for information purposes only.