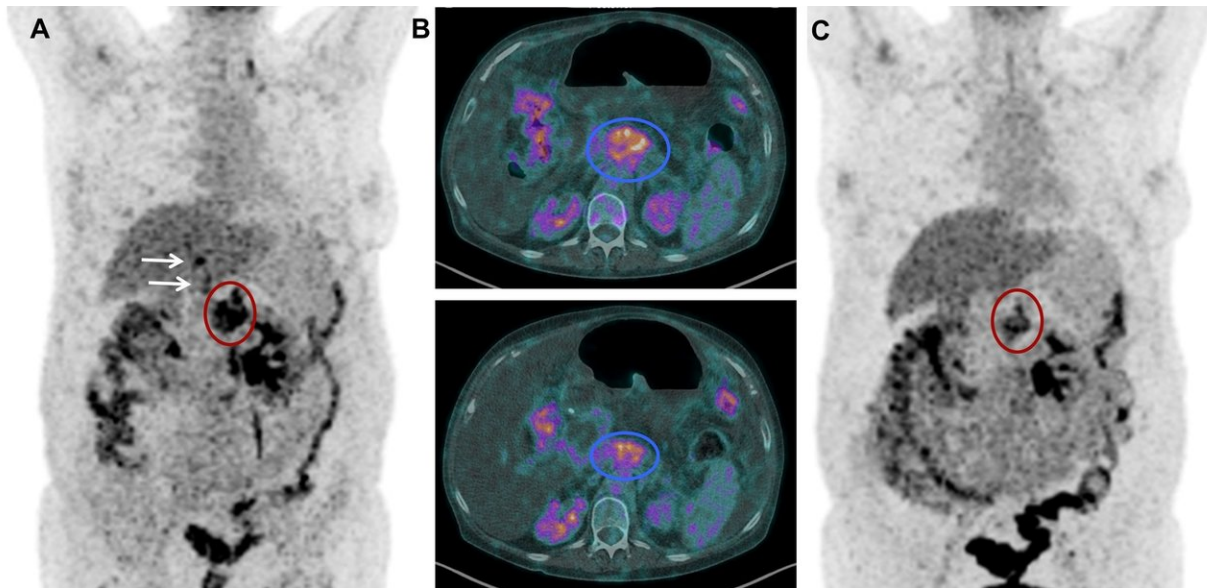


Novel theranostic approach for treating pancreatic cancer patients shows promise

May 1 2018



(A) ¹⁸F-FDG PET before ¹⁷⁷Lu-3BP-227 therapy. Red oval: primary tumor; arrows: liver metastases. (B, upper panel) Axial CT section; primary tumor (blue oval) before ¹⁷⁷Lu-3BP-227 therapy. (B, lower panel) Axial CT section; primary tumor (blue oval) after 3 cycles of ¹⁷⁷Lu-3BP-227 therapy. (C) ¹⁸F-FDG PET after 3 cycles of ¹⁷⁷Lu-3BP-227 therapy. Credit: RP Baum, A Singh et al., THERANOSTICS Center for Molecular Radiotherapy and Molecular Imaging, Zentralklinik Bad Berka, Bad Berka, Germany

German researchers have developed a novel diagnostic and therapeutic (theranostic) procedure for patients with ductal pancreatic

adenocarcinoma, a deadly cancer with an extremely poor prognosis (five-year survival rate of less than 5 percent) and limited treatment options. The study is featured in the May issue of *The Journal of Nuclear Medicine*.

In early preclinical studies with animal models, the novel procedure significantly inhibited tumor growth. Focusing on the neurotensin receptor 1 (NTR1), a protein that is overexpressed in ductal pancreatic adenocarcinoma, researchers developed a DOTA-conjugated NTR1 antagonist 3BP-227 labeled with the radioisotope lutetium-¹⁷⁷ (¹⁷⁷Lu) to treat and monitor therapy.

For this study, 6 [patients](#) with confirmed metastatic ductal pancreatic adenocarcinoma, who had exhausted all other [treatment](#) options, received ¹⁷⁷Lu-3BP-227 as salvage therapy. Scintigraphy and single-photon emission [computed tomography](#) was used with computed tomography (SPECT/CT) to determine the tumor uptake and the patients' eligibility for treatment. If the patient's condition allowed, ¹⁸F-FDG [positron emission tomography](#) (PET)/CT imaging was performed 8-12 weeks after therapy to determine treatment efficacy.

¹⁷⁷Lu-3BP-227 was well tolerated by all patients, with the most severe adverse reaction a reversible grade 2 anemia. One patient experienced significant improvement of symptoms and quality of life—surviving 13 months from diagnosis and 11 months from the start of ¹⁷⁷Lu-3BP-227 therapy.

This study provides the first clinical evidence of the feasibility of treating ductal pancreatic adenocarcinoma using ¹⁷⁷Lu-3BP-227.

"The research presented warrants further development of ¹⁷⁷Lu-3BP-227, in order to provide patients with more [effective treatment](#) and less side effects than cytotoxic chemotherapy," explains Christiane

Smerling, PhD, head of Nuclear Medicine and Imaging at 3B Pharmaceuticals GmbH in Berlin, Germany.

She points out, "Exploiting a hitherto underexplored receptor, these findings broaden the scope of [nuclear medicine](#) treatment for pancreatic adenocarcinoma and potentially other indications expressing neurotensin receptors, such as Ewing sarcoma. A theranostic approach using molecular imaging to identify potential responders will allow more effective treatment of a highly underserved patient population."

More information: Richard P. Baum et al, ¹⁷⁷Lu-3BP-227 for Neurotensin Receptor 1–Targeted Therapy of Metastatic Pancreatic Adenocarcinoma: First Clinical Results, *Journal of Nuclear Medicine* (2017). [DOI: 10.2967/jnumed.117.193847](https://doi.org/10.2967/jnumed.117.193847)

Provided by Society of Nuclear Medicine and Molecular Imaging

Citation: Novel theranostic approach for treating pancreatic cancer patients shows promise (2018, May 1) retrieved 29 March 2023 from <https://medicalxpress.com/news/2018-05-theranostic-approach-pancreatic-cancer-patients.html>

This document is subject to copyright. Apart from any fair dealing for the purpose of private study or research, no part may be reproduced without the written permission. The content is provided for information purposes only.