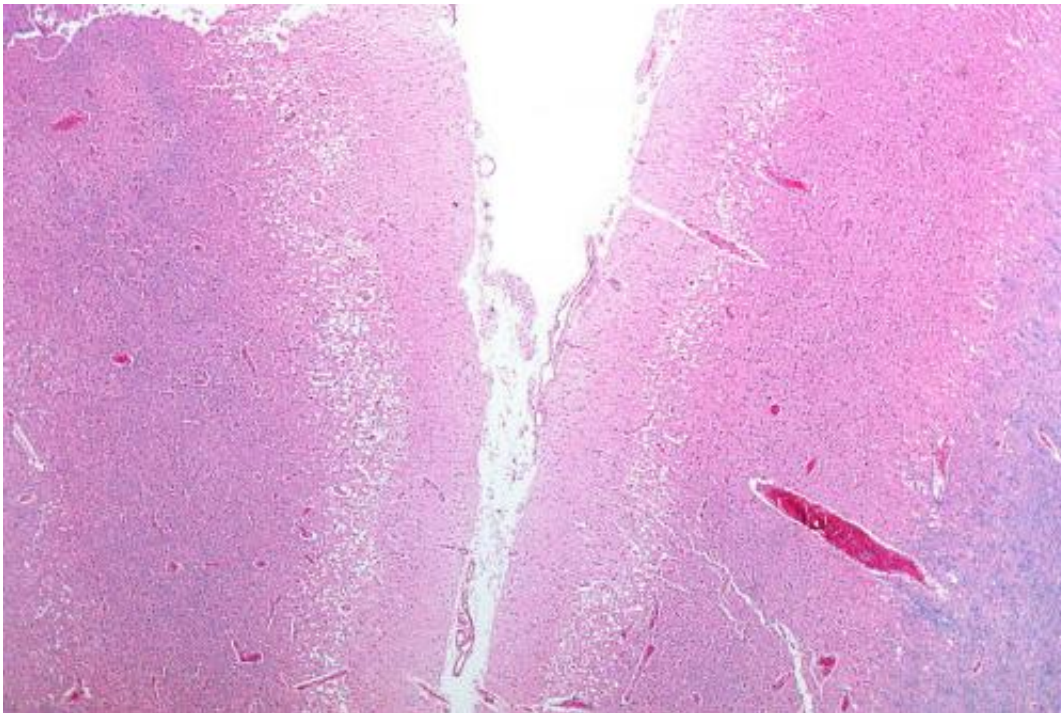


Endovascular therapy potentially beneficial for distal stroke clots

September 12 2016



Micrograph showing cortical pseudolaminar necrosis, a finding seen in strokes on medical imaging and at autopsy. H&E-LFB stain. Credit: Nephron/Wikipedia

Endovascular therapy for disabling strokes caused by a blockage in a more distal portion of a large vessel is effective and possibly superior to best medical management, according to a large multicenter retrospective study by The University of Texas Health Science Center at Houston (UTHealth).

The results were published today in *JAMA Neurology*, a journal of the American Medical Association.

Strokes that form in large vessels such as the internal carotid artery are known to be less responsive to the clot-buster [tissue plasminogen activator](#) (tPA), the only known medication to treat stroke. These large vessel occlusions are more likely to result in major disabilities and long-term care.

Endovascular therapy is the mechanical removal of a clot occluding a vessel. A catheter is deployed through an artery in the groin up to the site of the clot and the clot is captured and removed. It has been shown to be effective for blockages in the first segment of the internal carotid artery and is now standard of care for that type.

But researchers had not determined whether it was also safe and potentially effective for occlusions in the second, more distant segment of the internal [carotid artery](#), known as M2.

First author Amrou Sarraj, M.D., assistant professor of neurology at McGovern Medical School at UTHealth and attending physician at Misher Neuroscience Institute at Memorial Hermann-Texas Medical Center, reviewed a pool of ischemic stroke [patients](#) from 10 sites across the country.

The study, which presents the largest and most comprehensive cohort available, examined 522 patients with large vessel occlusion in the M2 segment. Of those patients, 288 received [endovascular treatment](#) and 234 received best medical management. The rate of good outcomes was higher - 63 percent - in the endovascular group compared to 36 percent in the [medical management](#) group, showing that endovascular therapy significantly increases patients' likelihood of independence and returning to normal activities as compared to medical treatment including the clot-

busting medication.

"This is a group of stroke patients that has been underrepresented in trials testing endovascular treatment for strokes. Further research in the form of a randomized clinical trial needs to be done to confirm our findings," Sarraj said. "We hope that in the meantime, the results of this study support that patients with M2 occlusions who have disabling neurological deficits should be heavily considered and probably treated with endovascular therapy to give them the best chance of a better outcome."

More information: Amrou Sarraj et al, Endovascular Therapy for Acute Ischemic Stroke With Occlusion of the Middle Cerebral Artery M2 Segment, *JAMA Neurology* (2016). [DOI: 10.1001/jamaneurol.2016.2773](https://doi.org/10.1001/jamaneurol.2016.2773)

Provided by University of Texas Health Science Center at Houston

Citation: Endovascular therapy potentially beneficial for distal stroke clots (2016, September 12) retrieved 19 January 2024 from <https://medicalxpress.com/news/2016-09-endovascular-therapy-potentially-beneficial-distal.html>

<p>This document is subject to copyright. Apart from any fair dealing for the purpose of private study or research, no part may be reproduced without the written permission. The content is provided for information purposes only.</p>
--