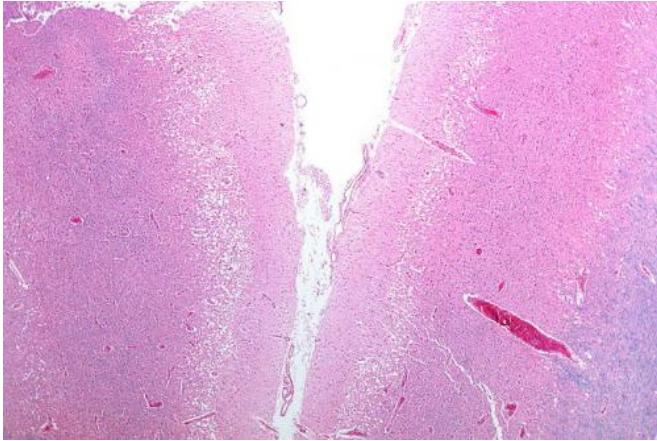


# Risk of stroke at time of carotid occlusion

21 September 2015



Micrograph showing cortical pseudolaminar necrosis, a finding seen in strokes on medical imaging and at autopsy. H&E-LFB stain. Credit: Nephron/Wikipedia

Preventing carotid artery occlusion (blockage) may not be a valid indication for stenting because the risk of progression to occlusion appears to be below the risk of carotid stenting or endarterectomy (surgical removal of plaque from an artery), according to an article published online by *JAMA Neurology*.

Increasing evidence indicates that with intensive medical therapy most patients with asymptomatic [carotid](#) stenosis (ACS) are more likely to be harmed than to benefit from [carotid endarterectomy](#) or carotid stenting. Many of these procedures are performed with the objective to prevent carotid occlusion because the underlying assumption is that carotid occlusion would carry a high risk of stroke.

J. David Spence, M.D., of Western University, Ontario, Canada, and coauthors looked at the risk resulting from progression to occlusion among patients with ACS. They assessed the role of severity of carotid stenosis or the presence of contralateral (on the opposite side of the body) occlusion as factors that may predict the risk of

stroke or death after occlusion of a previously asymptomatic carotid stenosis.

The authors analyzed data collected from patients at stroke prevention clinics from 1990 through 1995 or from 1995 through 2012. The authors measured ipsilateral stroke (on the same side of the body as the carotid artery blockage), [transient ischemic attack](#), death from ipsilateral stroke or death from unknown cause.

The study reports that among 3,681 patients, 316 patients were asymptomatic before the initial occlusion. The average age of patients was 66, most patients were men and most had high blood pressure and hyperlipidemia. Most new occlusions (254 of 316) occurred before 2002, when medical therapy was less intensive.

Only one patient (0.3 percent) had a stroke at the time of the occlusion and only three patients (0.9 percent) had an ipsilateral stroke during follow-up. Analyses suggest that neither severity of stenosis nor contralateral occlusion predicted the risk of ipsilateral stroke or transient ischemic attack, death from stroke or death from unknown cause.

"Patients with carotid stenosis are at high risk of death, but as indicated in Table 2, most of the deaths are not from stroke. Carotid stenting or endarterectomy can therefore not be expected to improve those outcomes," the study notes.

Study limitations include that authors did not perform brain imaging unless patients had a stroke and they did not study patients who became symptomatic and had interventions for that reason.

"The risk of ipsilateral stroke at the time of carotid occlusion was well below the risk of [carotid stenting](#) or carotid endarterectomy, and the percent stenosis or contralateral occlusion did not identify patients who would benefit from intervention. Preventing carotid occlusion may not be a valid indication for intervention," the study concludes.

In a related editorial, Seemant Chaturvedi, M.D., and Ralph L. Sacco, M.D., M.S., of the University of Miami Miller School of Medicine, write: "In this issue of *JAMA Neurology*, Yang et al add some 'fuel to the fire' regarding the debate concerning the best treatment for [asymptomatic carotid stenosis](#). ... As a single-center study, the analysis by Yang et al has limitations. ... All these limitations could have led to underestimations in the risk of [stroke](#). ... Ultimately, whether the improvements in aggressive [medical therapy](#) are sufficient to reduce the rationale for CEA (carotid endarterectomy) or CAS ([carotid artery](#) stenting) in asymptomatic [patients](#) will need to be determined by contemporary randomized clinical trials."

**More information:** JAMA Neurol. Published online September 21, 2015. [DOI: 10.1001/jamaneurol.2015.1843](#)

JAMA Neurol. Published online September 21, 2015. [DOI: 10.1001/jamaneurol.2015.2196](#)

Provided by The JAMA Network Journals

APA citation: Risk of stroke at time of carotid occlusion (2015, September 21) retrieved 19 June 2021 from <https://medicalxpress.com/news/2015-09-carotid-occlusion.html>

*This document is subject to copyright. Apart from any fair dealing for the purpose of private study or research, no part may be reproduced without the written permission. The content is provided for information purposes only.*