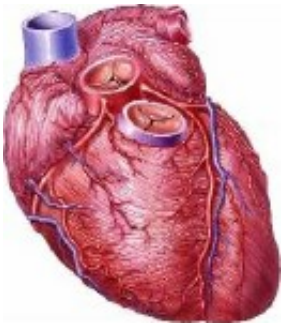


Post-op myocardial necrosis common after orthopedic sx

June 3 2015



(HealthDay)—Myocardial necrosis is common after orthopedic surgery and is associated with increased risk of long-term mortality, according to a study published in the June 15 issue of *The American Journal of Cardiology*.

Brandon S. Oberweis, M.D., from the Columbia University Medical Center in New York City, and colleagues examined the correlation between perioperative troponin elevation and long-term mortality in a retrospective study of patients who underwent hip, knee, and spine surgery. Data were included for 3,050 patients who underwent surgery (mean age, 60.8 years); postoperative troponin was measured in 34.6 percent of patients.

The researchers found that [myocardial necrosis](#) occurred in 5.9 percent

of cases, and myocardial infarction was coded in 0.7 percent of cases. During 9,015 patient-years of follow-up, there were 111 deaths (3.6 percent). In patients with myocardial necrosis, long-term mortality was 16.8 percent, while mortality was 5.8 percent for those with troponin in the normal range. After multivariable adjustment, perioperative troponin elevation and coded postoperative myocardial infarction were significantly correlated with long-term mortality (hazard ratios, 2.33 and 3.51, respectively). Myocardial necrosis remained associated with long-term mortality after exclusion of patients with [coronary artery disease](#) and renal dysfunction.

"In conclusion, postoperative myocardial necrosis is common after [orthopedic surgery](#)," the authors write. "Myocardial necrosis is independently associated with long-term mortality at three years and may be used to identify patients at higher risk for events who may benefit from aggressive management of cardiovascular risk factors."

More information: [Abstract](#)
[Full Text \(subscription or payment may be required\)](#)

Copyright © 2015 [HealthDay](#). All rights reserved.

Citation: Post-op myocardial necrosis common after orthopedic sx (2015, June 3) retrieved 18 December 2023 from <https://medicalxpress.com/news/2015-06-post-op-myocardial-necrosis-common-orthopedic.html>

| |
|--|
| <p>This document is subject to copyright. Apart from any fair dealing for the purpose of private study or research, no part may be reproduced without the written permission. The content is provided for information purposes only.</p> |
|--|