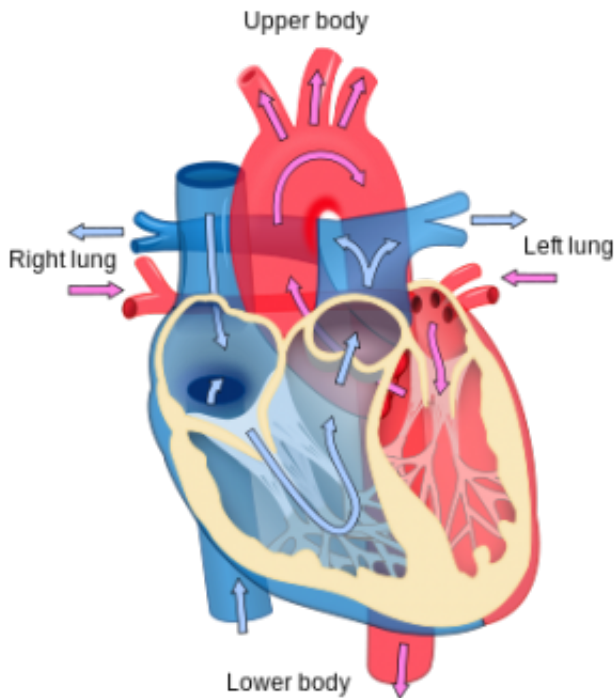


Ultrasound promising for detecting potential heart attacks, stroke before symptoms arise

12 January 2015



Heart diagram. Credit: Wikipedia

A study of portable ultrasound carried out in the USA, Canada and India has revealed the potential of this technology for detecting plaques in peripheral arteries that can lead to heart attacks and stroke before symptoms arise, in both developed and developing country settings, allowing preventive treatment in those affected. The study, published in *Global Heart* (the journal of the World Heart Federation), is by Dr Ram Bedi, Affiliate Assistant Professor, Department of Bioengineering, University of Washington, Seattle, WA, USA, and Professor Jagat Narula, Editor-in-Chief of *Global Heart* and Icahn School of Medicine at Mount Sinai, New York, USA, and colleagues.

Numerous research studies have shown that it is possible to assess subclinical atherosclerotic

cardiovascular disease (ASCVD) using [ultrasound imaging](#). Since more portable and lower cost [ultrasound](#) devices are now entering the market, along with increased automation and functionality, it may be possible in future to routinely examine people with ultrasound to establish any ASCVD present before symptoms emerge, so that future disease can be prevented, for example using medication. In this study, ASCVD was determined using ultrasound of both the carotid arteries (those in the neck) and the iliofemoral arteries (entering the top of the leg). The findings were conveniently summarised in an easy to understand index called the Fuster-Narula (FUN) Score.

Data were gathered from 4 cohorts, 2 Indian and 2 North American. In India, a medical camp setting was used, and screening with automated ultrasound imaging was conducted over 8 days in 941 relatively young (mean age 44 years, 34% female) asymptomatic volunteers recruited from the semiurban town of Sirsa (Haryana) and urban city of Jaipur (Rajasthan) in northern India. The cohort from Sirsa was specifically recruited because all participants had already undergone aggressive lifestyle changes (smoking cessation, no alcohol, vegetarian diet, physically active lifestyles, daily meditation), Radiology resident doctors who had no prior training in vascular ultrasound were trained on the spot to perform the ultrasound examinations.

To compare the imaging findings with traditional risk factors, 2 cohorts (481 persons) were recruited from primary care clinics in North America (one in Richmond, Texas, USA, the other in Toronto, Canada). As well as the same ultrasound examinations given in the Indian cohort, comprehensive ASCVD risk factor data was gathered from these participants, all of whom were self-referred asymptomatic individuals (mean age 60 years, 39% female). Data collected included cholesterol levels, blood pressure, glucose level, weight, height, smoking and family history. These people were attending clinics for routine health

examinations in most cases. Effectiveness of established ASCVD prevention guidelines was then compared to results from direct imaging. Ultrasound was performed by trained experts at each centre.

In India, ultrasound revealed plaques in at least one artery in almost a quarter (24%) of those examined; 107 (11%) had plaques in only the carotids, 70 (7%) in both the carotids and iliofemoral arteries, and 47 (5%) had plaques in only the iliofemoral arteries. If just the carotids had been examined, 177 (19%) of the asymptomatic subjects would have been identified with plaques; by adding the iliofemoral examination, 47 additional individuals (5% of the total) were identified with plaque. Older age and male sex were associated with the presence of plaque both in urban and semiurban populations (the much higher levels of smoking in men could account for their higher risk).

Data from the American and Canadian clinics showed that 203 subjects (42%) had carotid plaque; 166 of these (82% of those with plaque) would not have qualified for lipid-lowering therapy such as statins under the most widely used guidelines known as ATP III (Third Report of the Expert Panel on Detection, Evaluation, and Treatment of High Blood Cholesterol in Adults [Adult Treatment Panel]) guidelines. Using the recently published more stringent ATP IV guidelines, 67 people (one third of those with plaque and 14% of the total US/Canadian cohort) individuals with carotid plaque would also have failed to qualify for treatment.

In addition, the study revealed 34 people in the USA/Canada setting who qualified for treatment under ATP III but did not have any plaques, and this number increased to 81 under ATP IV (if receiving treatment such as statins, these people could be said to be overtreated, since no plaques were evident).

The authors say: "Our study shows that automation in ultrasound imaging technology allows even non-expert users to rapidly evaluate the presence of subclinical atherosclerosis in a large population. Detection of subclinical atherosclerosis is further enhanced by inclusion of the iliofemoral artery

examination."

They add: "It seems that plaque information from ultrasound images may serve as a guide for initiating medical intervention regardless of the availability or knowledge of traditional risk factors. Our results further suggest that not only in low- and middle-income countries, but even in the developed nations, ultrasound images may help refine strategies for medical intervention. It might however still be too contentious to suggest that risk factors-positive and imaging-negative asymptomatic subjects may be spared from medical intervention. Conversely, arguments against initiating medical intervention on risk factors-negative and imaging-positive asymptomatic subjects become harder to justify."

In a linked comment published with this paper, Dr Tasneem Z Naqvi, Professor of Medicine at the Mayo College of Medicine and Division of Cardiology, Scottsdale, Arizona, USA, adds: "This study shows that the assessment of subclinical atherosclerosis by a portable, user-friendly bedside tool is feasible in large populations and the technique of carotid ultrasound imaging and IMT assessment could be adopted by novices after an 8-hour crash course."

She concludes: "The study by Bedi et al puts into perspective the weakness of risk factor-based approach to identify individuals with subclinical atherosclerosis who are more likely to develop future cardiovascular events. The study shows that the vascular ultrasound imaging technology is ripe and that the previously existing barriers such as poor resolution, cumbersome protocols, need for off line processing and need for expert performer no longer exist. The question that this study does not address?and perhaps no study in future might?is whether this imaging based approach would save more lives than the risk-based approach. We need to ponder if treating nearly 50% of the adults with statins with a risk scoring algorithm (as happens in the USA) is more appropriate versus treating only those who have subclinical atherosclerosis based on comprehensive and readily available, cheap and simple screening method. This study makes a compelling argument in favour of imaging for screening."

In an additional comment, Professor Paul Leeson, a member of the Imaging Enhancement Expert Working Group for UK Biobank (with specific responsibility for the vascular imaging component), Professor of Cardiovascular Medicine at the University of Oxford and Clinical Director of the Oxford Cardiovascular Clinical Research Facility, UK, and not connected to the study or the journal, says: "Ultrasound seems to be firmly establishing itself as the advanced imaging technology of choice for global health care issues. Current ultrasound scanners generate accurate cardiovascular measures safely, rapidly and relatively inexpensively. This paper nicely demonstrates how people with little imaging experience can undergo a short training programme and then use portable ultrasound systems in a wide variety of global health care settings. The fact this imaging technology can be applied to large populations has also made it an attractive option for many of the major biobank research projects, such as UK Biobank. These projects are planned to generate vascular images for hundreds of thousands of individuals in different countries that, over the next few years, can be used to determine the true value of vascular imaging for disease prediction."

Provided by World Heart Federation

APA citation: Ultrasound promising for detecting potential heart attacks, stroke before symptoms arise (2015, January 12) retrieved 28 April 2021 from <https://medicalxpress.com/news/2015-01-ultrasound-potential-heart-symptoms.html>

This document is subject to copyright. Apart from any fair dealing for the purpose of private study or research, no part may be reproduced without the written permission. The content is provided for information purposes only.