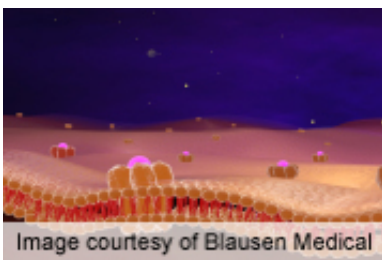


Pulmonary artery enlargement predicts exacerbation in COPD

September 4 2012



For patients with chronic obstructive pulmonary disease, computed tomographic measurement of pulmonary artery enlargement, as determined by a ratio of the diameter of the pulmonary artery to the diameter of the aorta of >1 , correlates with severe exacerbations, according to a study published online Sept. 3 in the *New England Journal of Medicine* to coincide with presentation at the annual meeting of the European Respiratory Society, held from Sept. 1 to 5 in Vienna.

(HealthDay)—For patients with chronic obstructive pulmonary disease (COPD), computed tomographic (CT) measurement of pulmonary artery enlargement, as determined by a ratio of the diameter of the pulmonary artery to the diameter of the aorta (PA:A) of >1 , correlates with severe exacerbations, according to a study published online Sept. 3 in the *New England Journal of Medicine* to coincide with presentation at the annual meeting of the European Respiratory Society, held from Sept. 1 to 5 in Vienna.

J. Michael Wells, M.D., from the University of Alabama at Birmingham,

and colleagues conducted a multicenter observational trial involving former and current smokers with COPD to determine the association between a PA:A ratio of >1 and a history of severe exacerbations requiring hospitalization at the time of enrollment. The utility of the ratio was assessed as a predictor of events in longitudinal follow-up of this cohort and in an external validation cohort.

The researchers observed a significant association between a PA:A ratio of >1 and a history of severe exacerbations (odds ratio, 4.78). In both the trial cohort and the external validation cohort, a PA:A ratio of >1 correlated independently with an increased risk of future severe exacerbations (odds ratio, 3.44 and 2.80, respectively). PA:A ratio of >1 had the strongest association with severe exacerbations of all the variables analyzed.

"Pulmonary artery enlargement (a PA:A ratio of >1), as detected by CT, was associated with severe [exacerbations](#) of COPD," Wells and colleagues conclude.

Several authors disclosed [financial relationships](#) with pharmaceutical and biotechnology companies.

More information: [Abstract](#)

[Full Text](#)

[Editorial](#)

[More Information](#)

Copyright © 2012 [HealthDay](#). All rights reserved.

Citation: Pulmonary artery enlargement predicts exacerbation in COPD (2012, September 4)
retrieved 28 April 2023 from
<https://medicalxpress.com/news/2012-09-pulmonary-artery-enlargement-exacerbation-copd.html>

This document is subject to copyright. Apart from any fair dealing for the purpose of private study or research, no part may be reproduced without the written permission. The content is provided for information purposes only.