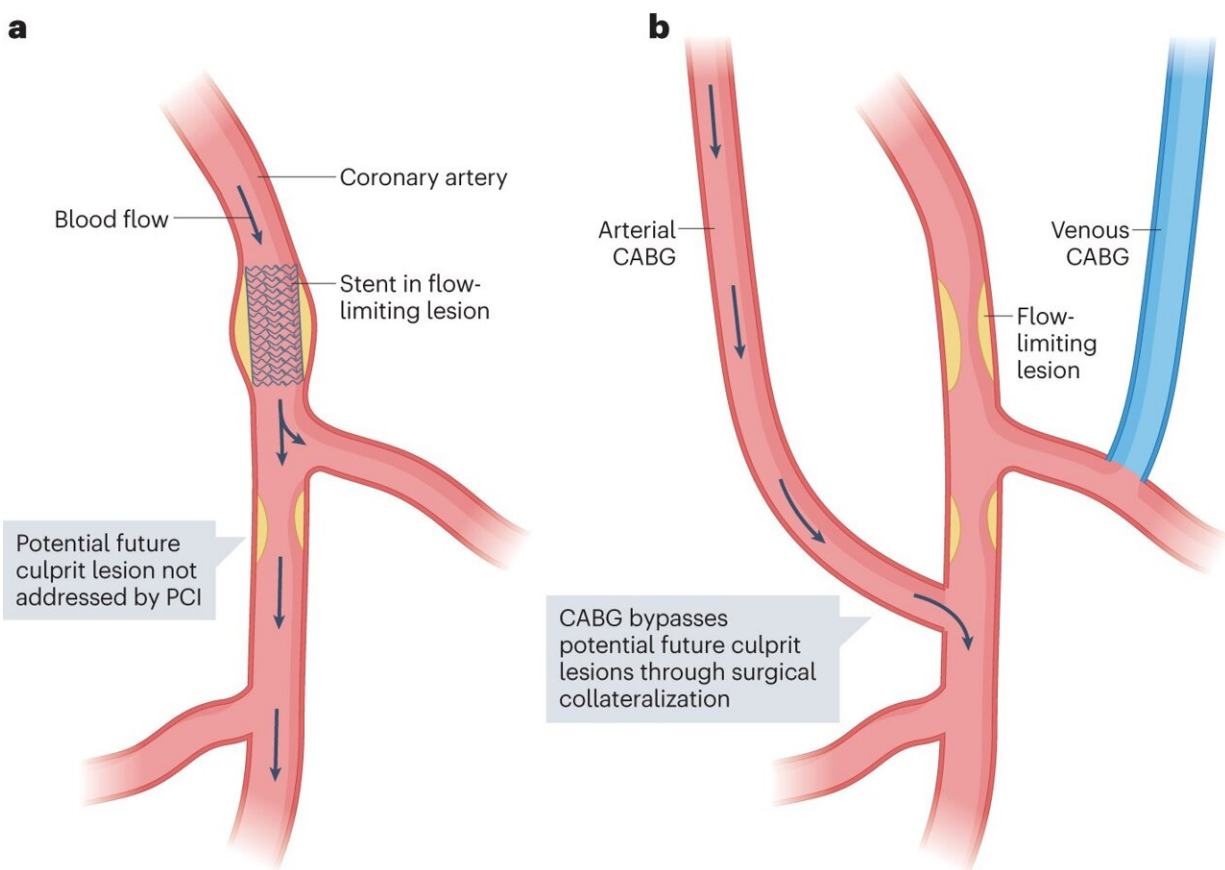


# Consensus recommendations for imaging of coronary artery stenosis and atherosclerosis

July 4 2023



Main differences in the revascularization concepts between PCI and CABG surgery. a, Percutaneous coronary intervention (PCI) has the advantage of re-establishing coronary artery blood flow after angioplasty and stent placement in a flow-limiting lesion. However, potential non-obstructive culprit lesions downstream of the stent are not treated, which could lead to infarction in distal vascular territories. b, By contrast, coronary artery bypass graft (CABG) surgery provides a bypass for alternative blood supply to distal coronary territories

(usually from an internal thoracic or radial artery or alternatively the saphenous vein), which has the advantage of protecting distal vascular territories because the grafts are usually inserted distally to additional plaque. Credit: *Nature Reviews Cardiology* (2023). DOI: 10.1038/s41569-023-00880-4

An interdisciplinary team of clinicians and scientists has published a consensus paper recommending appropriate quantitative imaging techniques for coronary artery stenosis and atherosclerosis related treatment and procedural planning. The paper has been published in *Nature Reviews Cardiology*.

Quantitative imaging has become increasingly important for the diagnosis of coronary artery disease (CAD) over the past five years. This is because new quantitative techniques can detect narrowed coronary arteries (coronary artery stenoses) and atherosclerosis, which play a major role in CHD patients.

It is important to correctly diagnose and accurately assess the severity of [coronary artery stenosis](#) or the extent of atherosclerotic burden for the selection of appropriate measures of therapy and the related further course of the disease. However, the complexity and variety of different quantitative imaging modalities, such as computed [tomography](#) (CT), [magnetic resonance imaging](#) (MRI), [invasive coronary angiography](#) (ICA), intravascular ultrasound (IVUS), and [optical coherence tomography](#) (OCT), necessitated a comprehensive clinical consensus.

## **Computed tomography is appropriate for suspected CAD with intermediate probability**

Experts from numerous disciplines, including radiology, cardiology, and [cardiac surgery](#), as well as engineering and computer science, have now

compared the current status of different quantitative imaging methods for coronary artery stenosis and atherosclerosis in detail in a consensus paper, evaluating the potential of each method.

According to the authors, the clinical consensus clearly stated two things. First, noninvasive CT should be considered the preferred method in patients with intermediate probability of CAD to exclude or confirm narrowed or occluded cardiac vessels (obstructive stenoses). CT allows the assessment of deposits in the coronary arteries in terms of size, composition, location, and associated risk of future cardiovascular disease.

Second, for patients presenting with acute symptoms or with a high probability of CAD, invasive methods such as ICA should be used preferred, including the possible addition of IVUS and OCT.

In addition, MRI can also facilitate the visualization of coronary plaques and serve as a radiation-free option for noninvasive coronary angiography in experienced centers. Positron emission tomography (PET) has the greatest potential for quantifying inflammation in coronary plaque.

Although ICA is considered by the authors to be the reference standard for the assessment of stenosis, the method does not allow the characterization of coronary plaques. For plaques at high risk of rupture, IVUS and OCT are considered the main invasive imaging modalities for identification.

## **Quantitative imaging allows for more objective diagnosis and assessment of treatment progress**

Prof. Dr. Marc Dewey, last author of the study expects the publication to change [clinical practice](#), "This paper provides an interdisciplinary

clinical consensus based on evidence-based data. It is a condensed summary and clearly maps current knowledge of each quantitative cardiovascular imaging procedure. Clinicians can thus be assisted in selecting the most appropriate method based on the specific clinical setting, individual patient characteristics, and availability of each procedure."

A total of seven methods were compared: Computed Tomography (CT), Magnetic Resonance Imaging (MRI), Positron Emission Tomography (PET), Single Photon Emission Computed Tomography (SPECT), Invasive Coronary Angiography (ICA), Intravascular Ultrasound (IVUS), and Optical Coherence Tomography (OCT).

The advantage of quantitative imaging over conventional diagnostics, which only visually displays the acquired images, is the additional acquisition of biophysical parameters. This leads to a more objective diagnosis and allows an assessment of the course of therapy. In [biomedical research](#) and clinical diagnostics, quantitative imaging thus enables changes in specific tissues of the body to be determined.

**More information:** Aldo J. Vázquez Mézquita et al, Clinical quantitative coronary artery stenosis and coronary atherosclerosis imaging: a Consensus Statement from the Quantitative Cardiovascular Imaging Study Group, *Nature Reviews Cardiology* (2023). [DOI: 10.1038/s41569-023-00880-4](#)

Provided by German Center for Cardiovascular Research

Citation: Consensus recommendations for imaging of coronary artery stenosis and atherosclerosis (2023, July 4) retrieved 4 July 2023 from <https://medicalxpress.com/news/2023-07-consensus-imaging-coronary-artery-stenosis.html>

This document is subject to copyright. Apart from any fair dealing for the purpose of private study or research, no part may be reproduced without the written permission. The content is provided for information purposes only.