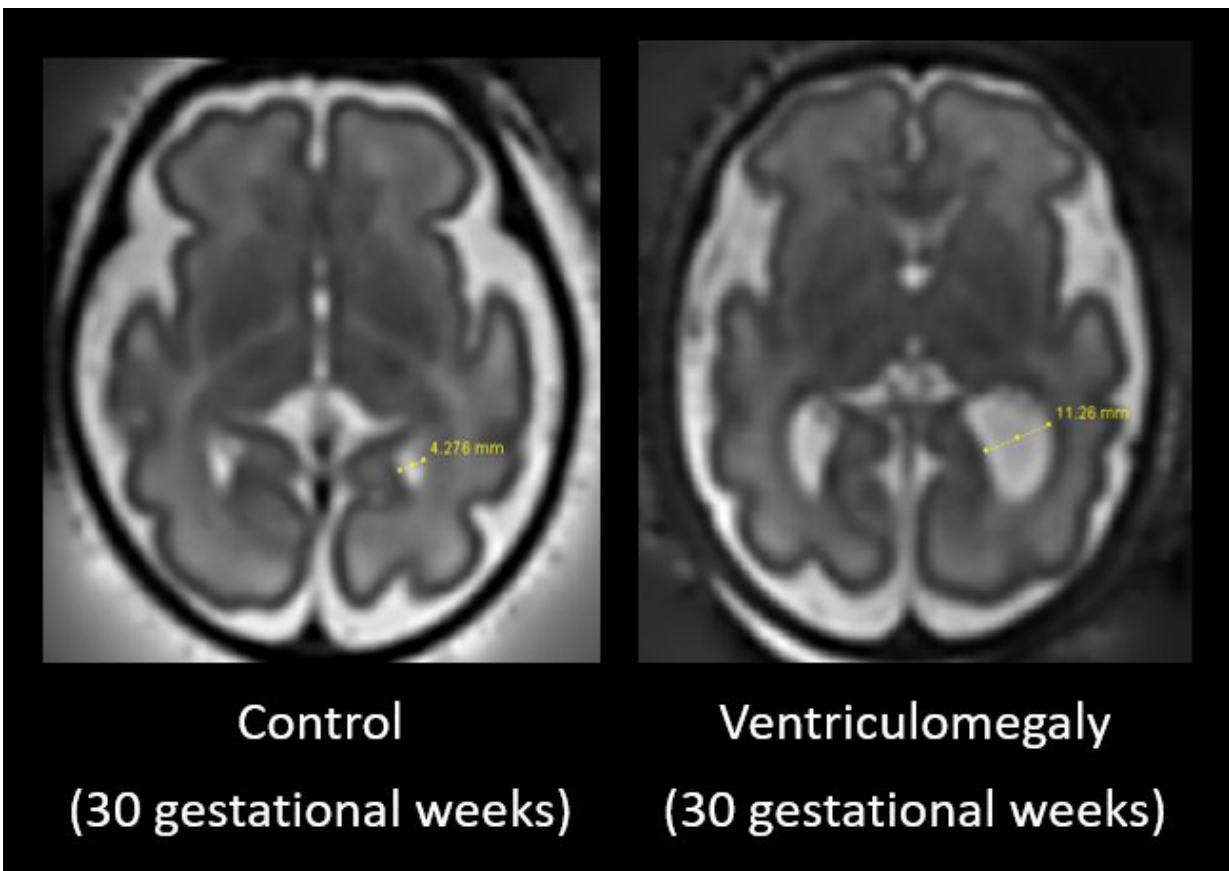


Fetal brain scan research examines early indicators of autism

April 19 2023



Credit: King's College London

Researchers have used MRI brain scans of children with isolated fetal ventriculomegaly to measure neurodevelopment and investigate the

presence of autism traits at school age.

In a paper published in *Nature Communications*, King's researchers from Centre for the Developing Brain have discovered evidence supporting an association between isolated ventriculomegaly and autism traits.

The study followed two groups of [children](#), one with a normal fetal [brain](#) MR assessment and those with an antenatal diagnosis of isolated ventriculomegaly, with a developmental follow up assessments at 2 years of age and primary school age.

Participating children were initially scanned as fetuses then tested with a range of developmental measures including IQ, autism traits, sustained attention, neurological functioning, behavior, executive function, sensory processing, co-ordination and adaptive behaviors.

Fetal ventriculomegaly is the most common antenatally-diagnosed brain abnormality and is diagnosed when the [lateral ventricles](#) measure larger than normal on antenatal ultrasound or MR imaging.

This study demonstrates an association between this most common developmental fetal brain anomaly and autism traits. The results may improve counseling for families and aid early identification, support and intervention, with further research warranted to confirm initial findings within a larger population.

"While this approach offers only a partial indicator of future outcomes, better prediction may have important implications for the long-term support of families. For example, early identification means that parents can be counseled on potential future outcomes and increased awareness of the onset of autism traits in their child would allow earlier and faster access to supporting programs," says Dr. Vanessa Kyriakopoulou, senior research associate in Neuroscience & Neuroimaging.

"There is a clear need for more long-term data combining high quality brain imaging with long term developmental follow up in children with antenatally-diagnosed isolated ventriculomegaly or indeed with other common fetal brain anomalies to improve our understanding about the susceptibility of developing [autism](#)," says Professor Mary Rutherford, Perinatal Imaging & Health.

More information: Vanessa Kyriakopoulou et al, Characterisation of ASD traits among a cohort of children with isolated fetal ventriculomegaly, *Nature Communications* (2023). [DOI: 10.1038/s41467-023-37242-0](#)

Provided by King's College London

Citation: Fetal brain scan research examines early indicators of autism (2023, April 19) retrieved 4 July 2023 from <https://medicalxpress.com/news/2023-04-fetal-brain-scan-early-indicators.html>

<p>This document is subject to copyright. Apart from any fair dealing for the purpose of private study or research, no part may be reproduced without the written permission. The content is provided for information purposes only.</p>
--