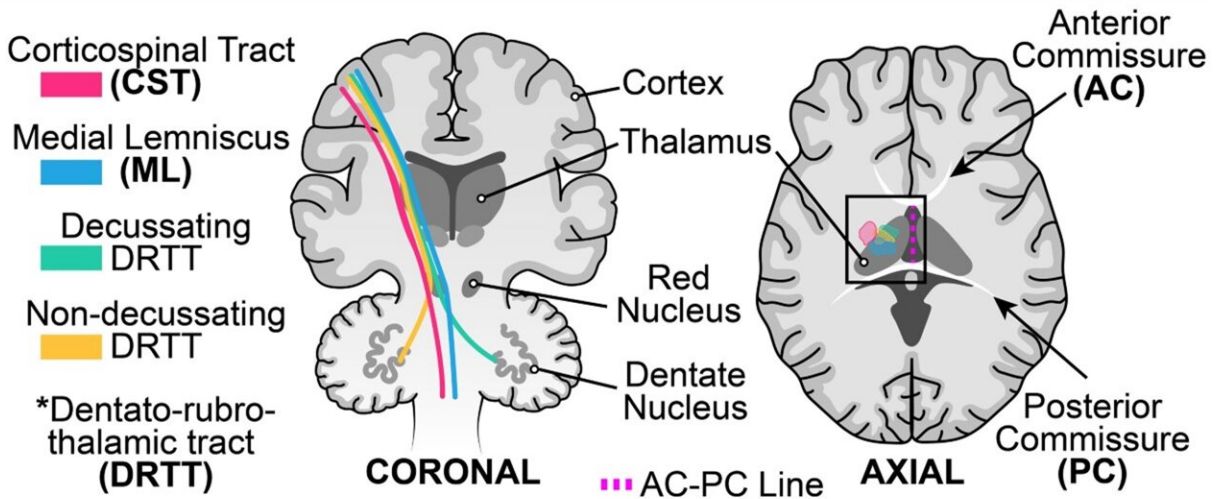


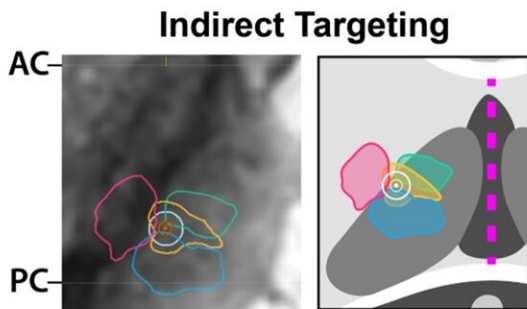
New technique improves high-intensity focused ultrasound treatment for brain disorders

December 28 2022

Four Fiber Tract Tractography

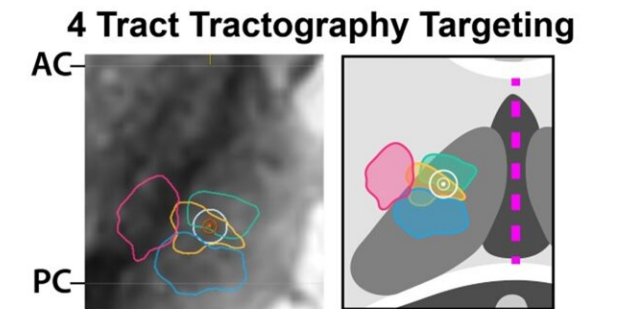


MRI Guided High Intensity Focused Ultrasound Targeting



Classic Indirect Target:
 25% of AC-PC anterior to PC
 14 mm lateral to AC-PC plane
 0-2 mm above AC-PC plane

ML and CST at risk



Tractography Target:
 Placed at most posterior overlap between decussating and non-decussating DRTT and modified* to avoid ML and CST.

ML and CST not at risk

*Margin based on patient's Skull Density Ratio (SDR)

Graphical abstract. Credit: *Brain Communications* (2022). DOI: 10.1093/braincomms/fcac273

UT Southwestern physicians have developed an improved targeting method, four-tract tractography, to personalize MRI-guided, high-intensity focused ultrasound (HIFU) used at UTSW to treat medication refractory tremor in essential tremor and tremor-dominant Parkinson's disease. Results of the clinical cases utilizing this approach, published in *Brain Communications*, suggest that it enables more precise targeting of the brain, decreases treatment times, reduces side effects and improves treatment response.

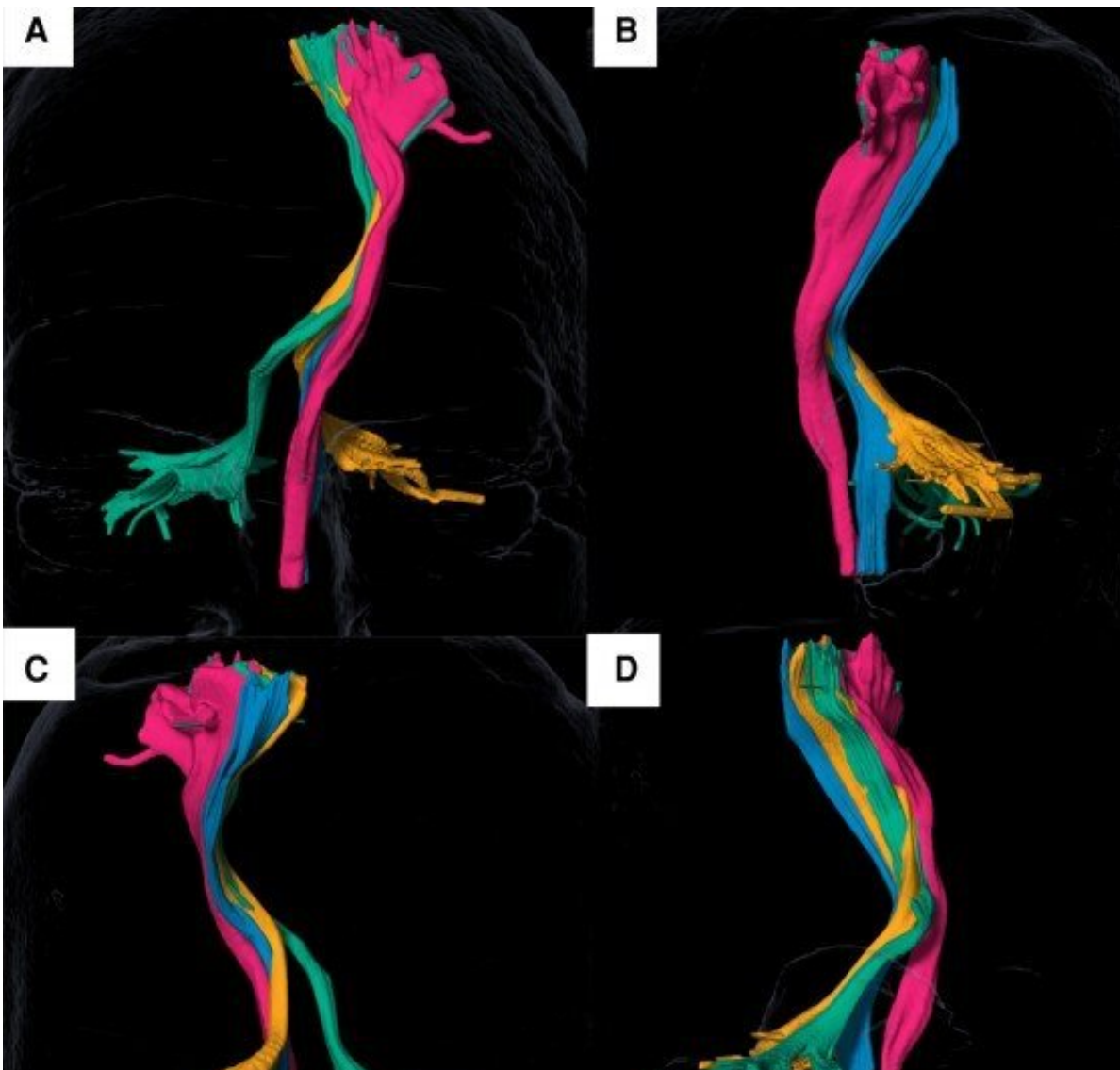
"Historically, the target for tremor could not be seen on standard high-resolution [magnetic resonance images](#), so landmark-based methods have been used," said Bhavya R. Shah, M.D., assistant professor of radiology and [neurological surgery](#), investigator in the Peter O'Donnell Jr. Brain Institute, and corresponding author. "By using tractography and other advanced magnetic resonance methods, we are working to identify the precise location of the target in individual patients and improve [patient outcomes](#)."

MRI-guided HIFU ablation of the ventral intermediate nucleus of the thalamus has been approved by the Food and Drug Administration for treatment of essential tremor and tremor-dominant Parkinson's. The efficacy and safety of the procedure are dependent on precise targeting; however, MRI cannot directly delineate the target. Thus, indirect methods using landmarks are utilized to identify the correct region.

Use of indirect targeting for HIFU ablation can result in significant

adverse side effects, including weakness, numbness, and paresthesia in nearly a third of patients one month post-treatment, that might be mitigated by using techniques to more directly target the region of the brain and identify regions to avoid.

To this end, the UT Southwestern physicians developed an improved, standardized four-tract tractography for HIFU using an FDA-approved surgical planning software that will allow for easy implementation into clinics.



Four-tract tractography identifies white-matter tracts in the brain, shown in 3D

renderings, for treatment with MRI-guided, high-intensity focused ultrasound (HIFU). Credit: UT Southwestern Medical Center

The four-tract tractography method builds off previous work by Dr. Shah, published in [Brain](#) in 2020, in which the researchers demonstrated the feasibility of advanced MRI techniques to identify tremor-associated white-matter tracts.

In the latest study, data were analyzed from 18 patients who underwent MRI-guided HIFU and had at least three months of follow-up post-treatment.

Use of the four-tract tractography for ablation suggests that this method yields decreased adverse effects. None of the patients experienced weakness, numbness, or paresthesia post-treatment; three patients experienced transient (three weeks) imbalance, common after magnetic resonance-guided HIFU.

Though this [retrospective review](#) was limited by a small sample size of patients treated in one center with a short follow-up, the results suggest promise for four-tract tractography to produce better outcomes for patients who need this procedure. A multicenter trial is planned with other U.S. sites, including the University of California San Francisco, the Mayo Clinic in Rochester, Minnesota, the University of Colorado, and an international site in Spain.

Several other sites have arranged to come to UTSW to work with Dr. Shah to learn his approach. This work represents a step forward in using advanced imaging to create personalized solutions for these patients, said Dr. Shah.

More information: Fabricio S Feltrin et al, Focused ultrasound using a novel targeting method four-tract tractography for magnetic resonance-guided high-intensity focused ultrasound targeting, *Brain Communications* (2022). [DOI: 10.1093/braincomms/fcac273](https://doi.org/10.1093/braincomms/fcac273)

Provided by UT Southwestern Medical Center

Citation: New technique improves high-intensity focused ultrasound treatment for brain disorders (2022, December 28) retrieved 13 July 2023 from <https://medicalxpress.com/news/2022-12-technique-high-intensity-focused-ultrasound-treatment.html>

This document is subject to copyright. Apart from any fair dealing for the purpose of private study or research, no part may be reproduced without the written permission. The content is provided for information purposes only.