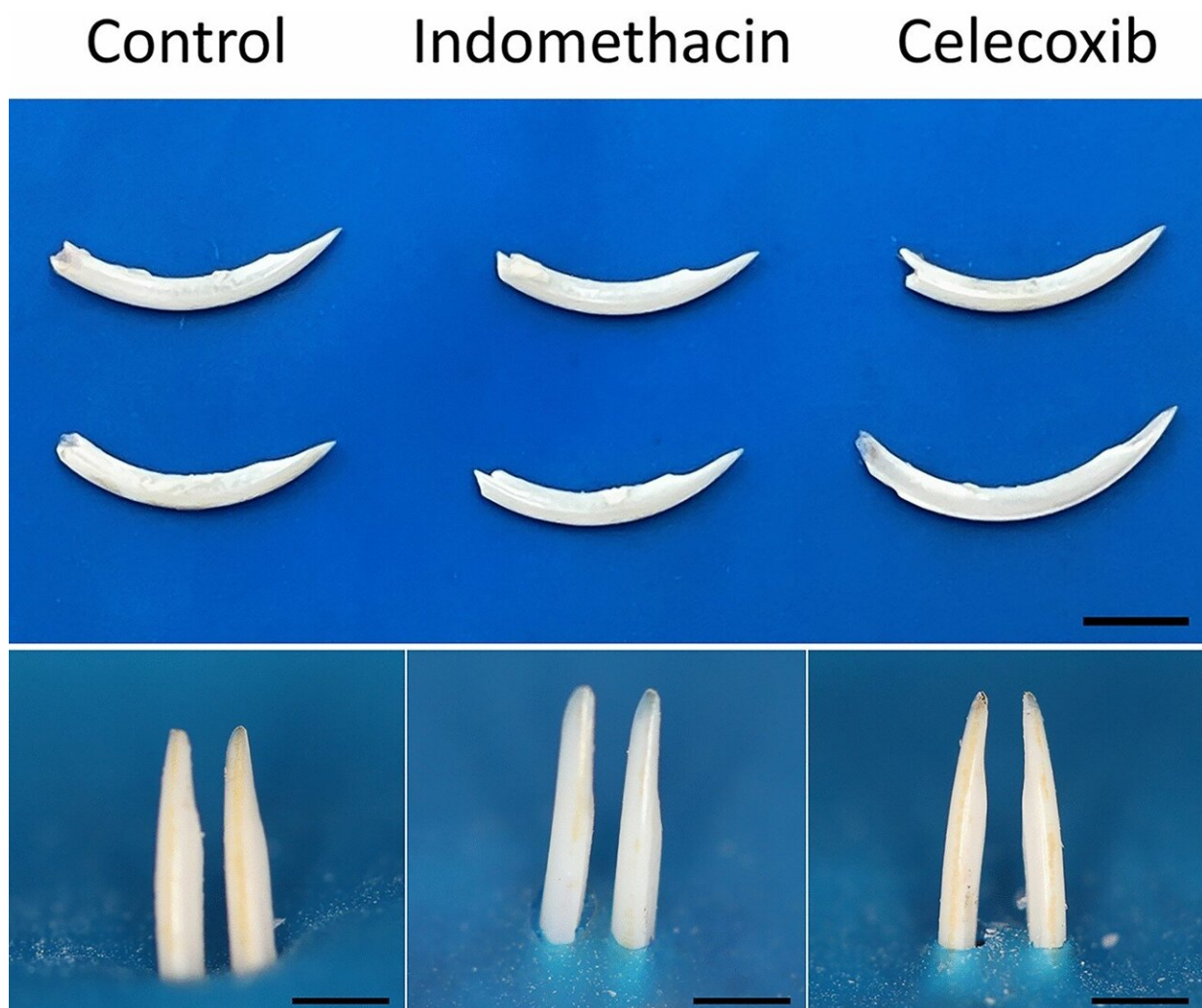


# Anti-inflammatory drugs commonly taken by children can cause alterations to dental enamel, study shows

December 20 2022, by Julia Moióli



Visual inspection of the dehydrated lower incisors of the mice treated or not with indomethacin and celecoxib (scale = 10 mm). Credit: *Scientific Reports* (2022).

DOI: 10.1038/s41598-022-19583-w

A study conducted at the University of São Paulo (USP) in Brazil and described in an article published in the journal *Scientific Reports* shows that anti-inflammatory drugs commonly taken by children may be associated with dental enamel defects (DEDs) currently seen in about 20% of children worldwide.

The authors, who are affiliated with the Ribeirão Preto Dental School (FORP-USP) and School of Pharmaceutical Sciences (FCFRP-USP), investigated the effects of celecoxib and indomethacin, non-steroidal [anti-inflammatory drugs](#) (NSAIDs) classified by the World Health Organization (WHO) as the first step on the analgesic ladder, alongside paracetamol.

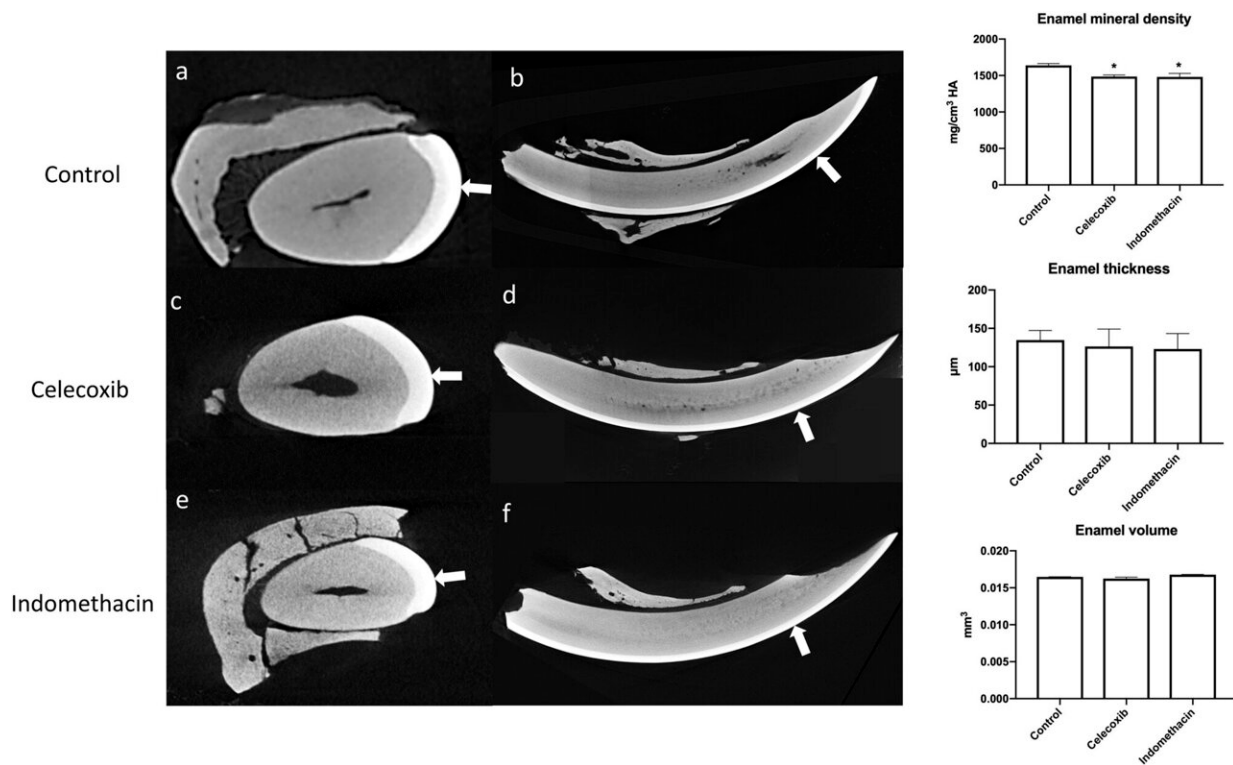
In recent years, dentists at FORP-USP's Dental Enamel Clinic, who research and deal with the problem on a daily basis, have observed a sharp rise in the number of children seeking treatment for pain, white or yellow tooth spots, and dental sensitivity and fragility. In some cases, simple chewing can fracture the children's teeth. All these are classical symptoms of DEDs of the type known as enamel hypomineralization, whose causes are poorly understood.

As a result of this disorder, [dental decay](#) in the form of carious lesions appears sooner and more frequently in these patients, whose restorations are less adhesive and tend to fail more. Studies have shown they may have to replace restorations ten times more often over a lifetime than people with healthy teeth.

A specific coincidence aroused the researchers' curiosity most of all: the patients' ages. The first years of life, when DEDs form, are a period in

which sickness is frequent, often with high fever.

"These diseases are typically treated with NSAIDs, which inhibit the activity of cyclooxygenase [COX, a key inflammatory enzyme] and reduce production of [prostaglandin](#) [which also promotes inflammation]," said Francisco de Paula-Silva, a professor in FORP-USP's Pediatric Department and last author of the article. "However, COX and prostaglandin are known to be physiological for dental enamel, and we therefore wondered whether these drugs interfered in the normal formation of this structure."



Micro-computed analysis ( $\mu$ CT) of mandibular incisors. Axial images (a,c,e) show the enamel layer of the three groups. In sagittal images (b,d,f) with white arrows that indicates the mature enamel segment which is about to erupt in oral cavity. Credit: *Scientific Reports* (2022). DOI: 10.1038/s41598-022-19583-w

The researchers used rats to study the problem, as these animals have incisors that grow continuously, which facilitates analysis. The rats were treated with celecoxib and indomethacin for 28 days, after which practically no differences in their teeth were visible to the naked eye. However, when the researchers began extracting, they found that the teeth fractured more easily.

Analysis based on imaging and chemical composition suggested that dental mineralization had been affected. The teeth contained below-normal levels of [calcium](#) and [phosphate](#), which are important to dental enamel formation, and mineral density was low.

When the researchers looked for the reasons for this, they found alterations in proteins required for mineralization and cellular differentiation, showing that the drugs had indeed affected the composition of the dental enamel.

## Next steps

"Right now, the study at least offers us a clue to the identity of a new player that may be involved in the development of DEDs. Hitherto we've been totally in the dark," said Paula-Silva. "We only achieved these important findings thanks to the efforts of FORP-USP's Dental Enamel Clinic and collaboration with Lúcia Helena Faccioli, a professor at FCFRP-USP. She made a crucial contribution to our understanding of the role played by lipidic mediators related to inflammatory diseases that affect teeth."

The group plans to conduct a clinical study with the aim of confirming the results of the research in the animal model. "We're going to analyze the medical history of the children with DEDs and their use of these drugs, and we'll set up a clinical study that will correlate the two datasets to see if the same thing happens to humans. If so, we can make

recommendations on which drugs shouldn't be used for which patients. We can also help work out an appropriate treatment protocol in future," said Paula-Silva, comparing this situation with that of tetracycline, an antibiotic not recommended for children because it causes tooth discoloration.

Another important point to be addressed is indiscriminate use of over-the-counter drugs, a problem that appears to have worsened as pediatric care has become more common, although concrete information on this is not yet available.

**More information:** Juliana de Lima Gonçalves et al, Enamel biomineralization under the effects of indomethacin and celecoxib non-steroidal anti-inflammatory drugs, *Scientific Reports* (2022). [DOI: 10.1038/s41598-022-19583-w](https://doi.org/10.1038/s41598-022-19583-w)

Provided by FAPESP

Citation: Anti-inflammatory drugs commonly taken by children can cause alterations to dental enamel, study shows (2022, December 20) retrieved 13 January 2023 from <https://medicalxpress.com/news/2022-12-anti-inflammatory-drugs-commonly-children-dental.html>

<p>This document is subject to copyright. Apart from any fair dealing for the purpose of private study or research, no part may be reproduced without the written permission. The content is provided for information purposes only.</p>
--