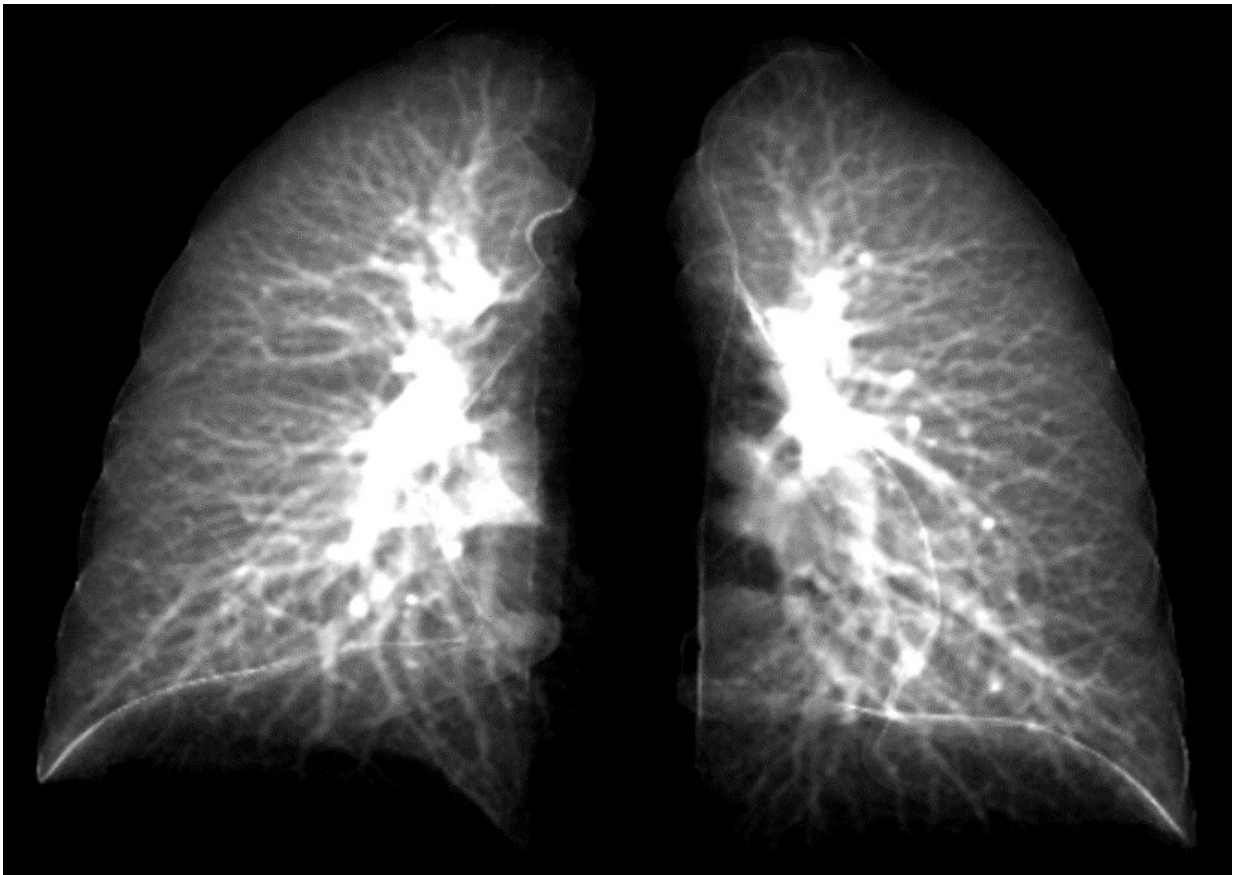


New model can detect long COVID's effects using simple, 2D chest X-rays

November 2 2022, by Richard C. Lewis



University of Iowa researchers have created an advanced model that can detect lung damage in long-COVID patients using a simple chest X-ray. The model takes data points from 2D lung images constructed from 3D CT lung scans. This image shows details of the lung in a 2D image. The model is attractive, because 2D chest X-ray equipment is more commonly available and less costly. Credit: Ching-Long Lin lab, University of Iowa

For patients dealing with lingering respiratory symptoms from the novel coronavirus, a chest X-ray can reveal only so much. The two-dimensional (2D) scans simply can't distinguish compromised lung function. For that diagnosis, a more expensive, three-dimensional (3D) technique called a CT scan is necessary.

Yet many [medical clinics](#) in the United States don't have CT scanning equipment, leaving so-called long-COVID patients with little information about their [lung function](#).

That may change. In a new study, researchers at the University of Iowa have developed what is called a contrastive learning model. This model "learns" from composite 2D images constructed from 3D CT images to detect compromised lung function in long-COVID patients. Another technique, called transfer learning, then conveys lung diagnostic information from a CT scan to a chest X-ray, thus allowing chest X-ray equipment to detect abnormalities the same as if those patients had used a CT scan.

In the study, the researchers showed how their contrastive learning model could be applied to detect small airways disease, which is an early stage of compromised lung function in long-COVID patients. Of the long-COVID patients, the models were advanced enough to distinguish the severity of the compromised lung function, separating those with small airways disease from those with more advanced respiratory issues.

"The new element to the model is taking information from 3D CT scans showing lung volume and transferring that information to a model that will show these same characteristics in 2D images," says Ching-Long Lin, Edward M. Mielnik and Samuel R. Harding professor and chair of the Department of Mechanical Engineering in the College of Engineering at Iowa. "Clinicians would be able to use chest X-rays to detect these outcomes. That's the bigger perspective."

The researchers based their modeling on CT scans of 100 people who were infected with the original COVID strain and went to UI Hospitals & Clinics for diagnosis for breathing problems between June and December 2020. Many of these long-COVID patients had small airways disease, a diagnosis reported by Alejandro Comellas, clinical professor of internal medicine–pulmonary, [critical care](#), and occupational medicine, in a paper published last March in the journal *Radiology*.

Small airways disease affects a network of more than 10,000 tubes at the nexus in the lung where oxygenated air mixes with blood to be carried throughout the body. People with small airways disease have many of these vessels constricted, thus limiting the oxygen-blood exchange in the lungs, and impeding breathing overall.

Lin and his team collected [data points](#) at two intervals in the CT lung scans—when the patient inhaled and when the patient exhaled. The researchers compared their results with a [control group](#) that had not contracted the virus as they created the contrastive learning model.

"Our models successfully identified decreased lung function from long-COVID patients compared to those who had not gotten the virus," says Lin, whose expertise is in machine learning and computational fluid and particle dynamic simulation.

Lin's team advanced the model so it could separate patients with small airways disease from those with more advanced complications, such as emphysema.

"The study demonstrated in an independent way that patients with post-COVID have two types of lung injuries (small airway disease and lung parenchyma fibrosis/inflammation) that are persistent after having recovered from their initial SARS CoV-2 infection," says Comellas, a co-author on this study.

"Chest X-rays are accessible, while CT scans are more expensive and not as accessible," Lin adds. "Our model can be further improved, and I believe there is potential for it to be used at all clinics without having to buy expensive imaging equipment, such as CT scanners."

The authors note the study is limited, in part because the sample size is small, and the patients are from a single medical facility. A larger sample size, they write, may uncover more variations in lung function stemming from long COVID.

The study was published in *Frontiers in Physiology*.

More information: Frank Li et al, Contrastive learning and subtyping of post-COVID-19 lung computed tomography images, *Frontiers in Physiology* (2022). [DOI: 10.3389/fphys.2022.999263](https://doi.org/10.3389/fphys.2022.999263)

Josalyn L. Cho et al, Quantitative Chest CT Assessment of Small Airways Disease in Post-Acute SARS-CoV-2 Infection, *Radiology* (2022). [DOI: 10.1148/radiol.212170](https://doi.org/10.1148/radiol.212170)

Provided by University of Iowa

Citation: New model can detect long COVID's effects using simple, 2D chest X-rays (2022, November 2) retrieved 10 April 2023 from <https://medicalxpress.com/news/2022-11-covid-effects-simple-2d-chest.html>

<p>This document is subject to copyright. Apart from any fair dealing for the purpose of private study or research, no part may be reproduced without the written permission. The content is provided for information purposes only.</p>
--