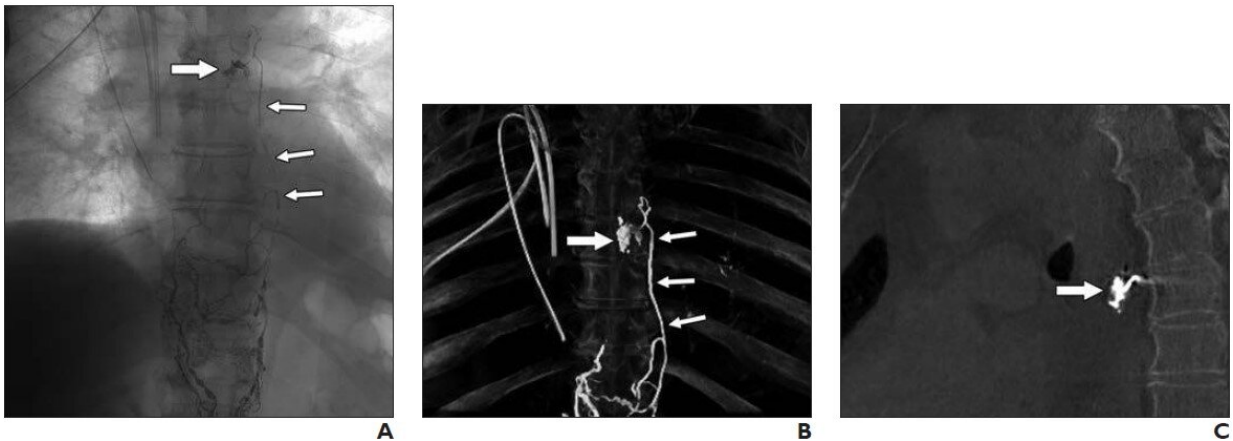


# Postop chylothorax treated with intranodal lymphangiography, ethiodized oil

June 14 2021



Plain thoracic radiograph (A), maximum intensity projection of cone-beam CT image (B), and sagittal cone-beam CT reconstruction (C) show ethiodized oil (Lipiodol Ultra Fluid, Guerbet) extravasation (thick arrow, A-C) projected at left main bronchus 6 days after esophagectomy and thoracic duct ligation were performed. Extravasation is supplied by mediastinal collateral lymph vessels (thin arrows, A and B). Credit: American Roentgen Ray Society (ARRS), *American Journal of Roentgenology* (AJR)

According to ARRS' *American Journal of Roentgenology* (AJR), high-dose intranodal lymphangiography (INL) with ethiodized oil is a safe and effective procedure for treating high-output postsurgical chylothorax with chest tube removal in 83% of patients.

"To our knowledge," wrote corresponding author Geert Maleux of University Hospitals in Leuven, Belgium, "no data are available on the safety or potential beneficial effect of injecting [higher doses](#) of ethiodized oil to treat patients with refractory postoperative chylothorax."

All 18 patients (mean, 67 years; range, 43-76 years) the Belgian researchers reviewed between May 2015 and March 2019 had undergone INL with high doses of Guerbet's Lipiodol Ultra Fluid (mean, 75 mL; range, 40-140 mL). Eleven patients (61%) had previously undergone thoracic duct ligation, though seven (39%) had not, while lymphangiography confirmed lymphatic leak in 12 of 18 patients (67%).

For five of the 18 patients (28%), a second INL was performed within 11 days (range, 5-15 days)—due to increasing [chest](#) tube output after initiation of a medium-chain triglyceride-enriched diet—with three of the five (60%) showing complete resolution after the second session. Ultimately, removal of all chest tubes proved possible in 15 of 18 patients (83%) after a mean of 12 days (range, 1-25 days).

"Despite the doses being many times higher than the dose recommended by the manufacturer," the authors of this AJR article added, "no early or late clinically relevant complications, including symptomatic pulmonary or paradoxical embolism, were recorded for any of the [patients](#)."

**More information:** Thomas Jardinet et al, Intranodal Lymphangiography With High-Dose Ethiodized Oil Shows Efficient Results in Patients With Refractory, High-Output Postsurgical Chylothorax: A Retrospective Study, *American Journal of Roentgenology* (2021). [DOI: 10.2214/AJR.20.23465](https://doi.org/10.2214/AJR.20.23465)

Provided by American Roentgen Ray Society

Citation: Postop chylothorax treated with intranodal lymphangiography, ethiodized oil (2021, June 14) retrieved 2 May 2023 from

<https://medicalxpress.com/news/2021-06-postop-chylothorax-intranodal-lymphangiography-ethiodized.html>

This document is subject to copyright. Apart from any fair dealing for the purpose of private study or research, no part may be reproduced without the written permission. The content is provided for information purposes only.